

D.Y. Ovsyannikov^{1,2}, M.A. Belyashova¹, A.A. Krushel'nitskii¹, A.A. Avakyan²,
N.O. Zaitseva², E.A. Degtyareva^{1,2}

¹ Peoples' Friendship University of Russia, Moscow

² Children's infectious diseases clinical hospital No. 6 of the Department of Healthcare of Moscow, Russian Federation

Wilson-Mikity syndrome – a rare interstitial pulmonary disease in neonates

Author affiliation:

Ovsyannikov Dmitrii Yur'evich, PhD, head of the pediatrics department at the Peoples' Friendship University of Russia

Address: 6 Miklukho-Maklaya Str., Moscow, 117198, **tel.:** +7 (499) 154-03-33,
e-mail: movsyannikov@yahoo.com

Article received: 20.10.2013. **Accepted for publication:** 24.02.2014.

Wilson-Mikity syndrome is an interstitial pulmonary disease of unknown etiology developing in neonatal period and characterized by late oxygen dependence development. The article cites data the possible etiological factors, pathogenesis, pathomorphology, clinical, X-ray and CT presentation of this rare disease. Having analyzed observations of patients with this syndrome (n=61) found in literature from 1960 to 2008, we identified relation of the syndrome's manifestation to age and degree of prematurity and disease outcomes. We present results of our observations of 6 patients with Wilson-Mikity syndrome, including data of high resolution computed tomography.

Keywords: *Wilson-Mikity syndrome, interstitial pulmonary diseases in neonates, diagnostics, clinical observations, high resolution computed tomography.*

Wilson-Mikity syndrome (WMS; P27.0 – ICD-10) is an interstitial pulmonary disease of unknown etiology in neonates; it forms in neonatality and is characterized by late development of oxygen dependence. The name of the disease is eponymous; it is derived from last names of the American doctors – pediatrician M.G. Wilson and radiologist V.G. Mikity – who observed a “new form of respiratory disease” in 5 premature infants with birth weight less than 1,800 g in 1960. In their article the authors stated that the disease would take an asymptomatic course for several postnatal days or even weeks and then manifest itself in the form of pronounced dyspnea and cyanosis. After that the patients would usually develop pulmonary heart symptoms. The described condition was characterized by normal body temperature and absence of inflammatory alterations (according to the complete blood count). Extensive laboratory tests did not reveal any infectious agents or systemic diseases associated with the observed pulmonary pathology. Moreover, specific radiographic alterations were detected in chest X-ray films of all the patients [1].

Since publication of the first WMS description, isolated cases of the disease were registered in Denver [2], Baltimore and Boston [3], New York [4], Switzerland [5], Canada [6], Australia [7], Italy [8], Nigeria [9], England [10] and other cities and countries. Apparently, the disease is geographically widespread. In Russia, nobody observed the disease more than V.F. Baklanova and M.I. Vladykina (12 times) [11]. For reasons unknown, the WMS rate has drastically reduced in recent years; its typical form has become rare. According to A. Hoepker et al., the WMS rate is less than 1:10,000 neonates [12].

WMS etiology remains unclear. Results of laboratory tests were negative in an overwhelming majority of cases. The tests included inoculations for bacteria and fungi, serologic tests for syphilis and respiratory viruses and Sabin-Feldman dye test for toxoplasmosis. The tests also included analysis of gastric lavage fluid for acid-fast bacteria, skin tests for tuberculosis,

coccidioidomycosis and histoplasmosis, which yielded negative results as well. Feces analyses revealed normal trypsin and chymotrypsin indicators. Bronchoscopy and bronchography of the WMS patients revealed normal bronchial tree structure. Biopsy tissue culture tests for viruses were in most cases negative [1-10]. However, J. Butterfield et al. revealed type 19 echovirus (ECHO) in one case [2]; C.H. Sinnette et al. revealed type 7 ECHO virus in nasopharynx of one child with WMS [9]. P. Reittner et al. published a case study of a child with WMS; histologic examination of the child's lung tissue detected cytomegalovirus particles in endothelial cells of venules and capillaries, in type II pneumocytes and alveolar macrophages [13].

E.D. Burnard et al. allowed that the only etiological factor of this syndrome is low (less than 32 weeks) gestational age (GA) [7]. A little later J.E. Hodgman et al. presented a case series of 29 WMS patients (the largest case series in the world), 5 of whom were born in the 33rd-36th gestational week [14].

Other authors allowed that WMS results from anatomic and functional underdevelopment of airways or repeated aspirations [15]. O.M. Bahdassarian et al. proposed a term for pulmonary alterations in children with WMS – “pulmonary immaturity”, although they did not perform quantitative analysis of alveolar proliferation in their patients [3].

M. Fujimura et al. revealed a high level of total immunoglobulin M in blood serum of children with WMS in the first postnatal day. This same group of authors described a high rate of WMS (similar to the rate of bronchopulmonary dysplasia (BPD) in neonates) in the children of women with chorioamnionitis [16, 17]. The level of elastase-proteinase inhibitory complex of polymorphonucleocytes was considerably higher in tracheal aspirates of children with WMS. It is considered that the increase results from an intrauterine infection and causes pulmonary injury and development of pulmonary emphysema (which is typical of WMS) [18]. Moreover, a high rate of vaginal hemorrhages during pregnancy had been observed in mothers of the children who developed WMS. Pregnancy and labor were often complicated by preterm rupture of fetal membranes, premature detachment of a normally positioned placenta and placenta previa [14].

Wilson-Mikity syndrome primarily develops in very low birth weight children born before the 32nd gestational week; according to our sources, its rate among the chronic diseases of underweight neonates is 4.3% [19]. The disease takes the severest course in the least mature infants. The disease usually manifests itself in the 5th-35th postnatal day; the available data also state that WMS may manifest itself as early as in the first postnatal day or as late as in the 15th postnatal week [1, 3, 9, 12, 14, 15, 20-25]. In several studies children with WMS developed neonatal respiratory distress syndrome (RDS) in the first postnatal days, which would require oxygen therapy and be terminated in the 3rd-4th postnatal day [12, 14].

According to the classic description by M.G. Wilson and V.G. Mikity confirmed by other studies, the first clinical symptoms of the disease are tachypnea, cyanosis, dyspnea (characterized by retraction of retractable sternal areas and intercostal spaces) and repeated apnea episodes, which may be accompanied by bradycardia [1]. Apnea is considered the disease's signature. As the disease progresses, cough, cyanosis (aggravating and becoming diffuse at exertion) and emphysematous chest distension develop. The respiratory rate often reaches 100 respiratory movements per minute. Respiratory failure results in oxygen dependence in all patients – this is another marker of this syndrome. Pulmonary rales are undetectable until the occurrence of cardiac failure. Fever occurs only in the event of development of an acute respiratory infection, which often results in a rehospitalization. Growth and development deviate from the norm only insignificantly, except for cases of infection overlay or development of such complications as pulmonary hypertension or pulmonary heart. If the disease course is favorable, respiratory failure symptoms slowly fade in the course of several weeks or months.

Pulmonary hypertension (PH) and pulmonary heart were considered the main causes of fatal outcomes in children with WMS. According to H. Grossman et al, suprasystemic pulmonary artery pressure levels were verified in 2 out of 5 children with the WMS complicated by pulmonary hypertension at right heart catheterization. Angiography revealed narrowing of peripheral segments of pulmonary arteries caused by extrusion of vessels by hyperinflated

segments of lungs in all patients [26]. The rate of PH at WMS has reduced in modern practice. Thus, according to A. Hoepker et al., PH was registered only in 1 out of the 8 observed children [12].

Distinctive radiographic alterations are observed at WMS. It ought to be mentioned that typical (sometimes even drastic) chest radiographic alterations are observed in some patients, whereas the symptoms are moderate or absent. Thus, in one child examined in the course of the first case series radiographic alterations were revealed 10 days before the first respiratory symptoms [1]. In other cases no radiographic pathological alterations are observed in the course of manifestation [14].

H. Grossman et al. proposed to distinguish between 3 radiographic stages of WMS: acute stage, intermediate stage and resolution stage. Chest radiography performed in the acute stage at the moment of occurrence of clinical symptoms reveal a bilateral reticulonodular or reticular pattern with small, circular transparent foci giving lungs a “bubbly” appearance. Another common sign is generalized hyperventilation. The radiographic pattern changes after several weeks or even months. The intermediate stage features crude stripe-like indurations coming from roots of the lungs; they are usually localized in the superior lobes. At the same time cystic lumps in bases of the lungs become larger and merge. Inferior lobes become hyperinflated and more transparent; the diaphragm flattens. Complete resolution and disappearance of radiographic alterations occur at the age of 3-24 months. Clinical recovery usually occurs before the resolution of radiographic alterations, which in some cases persist for months [4]. In the case series presented by J.E. Hodgman et al., steady hyperinflation of a certain part of lungs was observed in one patient at the age of 6 years despite the absence of the clinical symptoms; in all the other surviving infants complete resolution of the radiographic pattern was observed [14]. Other researchers distinguish between 2 radiographic stages of WMS. No pathological alterations are registered in the first stage in 50% of the patients, whereas diffuse cystic lumps and hyperinflation are revealed in the second stage [12].

P. Reittner et al. performed the first study utilizing the high resolution computed tomography (HRCT) at WMS. This study method allowed ascertaining involvement of small airways in the pathological process, as indicated by lobar hyperinflation and peribronchovascular and interlobar interstitial thickening accompanied by appearance of wide parenchymal stripes in the peripheral part of the lungs [13]. HRCT may also reveal atelectasis, trapped air and cystic lumps [12]. P. Reittner et al. put forward an assumption about a concurrent viral infection. Histologically, the interstitial thickening was associated with cellular inflammation and hyperplasia of smooth muscle fibers, which, according to the authors, are pathognomonic for WMS. Lobular hyperinflation segments were better visualized in the expiratory images. Use of HRCT at WMS allowed determining that complete resolution never occurs before the child reaches 7 months of age. According to the authors, HRCT plays a double role in the WMS patient management. Firstly, HRCT helps to specify the distinctive peculiarities of the disease in the early stages, when radiographic data are not specific: thus, it contributes to the beginning of early treatment and narrowing of the disease spectrum for differential diagnostics. Secondly, HRCT is very useful for determining localization and severity of the disease and the level of treatment efficiency [13]. Thus, WMS is a childhood interstitial pulmonary disease; this statement coincides with the opinion of A. Hoepker et al. [12]. This syndrome may also be classified as a small airway disease.

The data on 61 WMS cases published from 1960 to 2008 and found in the available literature are summarized in tb. 1.

Pathomorphological WMS alterations are as obvious as the radiographic alterations and closely correlate with occurrence thereof. Cross-sectional view of the lung at macroscopic examination has distinctive character: cirrhotic surface, marked interlobar fibrous septa and considerably enlarged lobes. Microscopic examination reveals thickening of interalveolar septa and cystic emphysematous alterations. Histiocytes and mononuclear leukocytes are often observed in the alveolar domain [6, 10, 15]. According to the electronic microscopy, pulmonary capillary

network is insufficiently developed [27]. These data support the opinion of the authors considering pulmonary involvement an indicator of dysmaturity rather than of emphysema. Unlike at BPD, signs of epithelial metaplasia and dysplasia are absent at WMS [15, 18]. Analyzing pulmonary alterations in the children undergoing artificial positive pressure pulmonary ventilation (APV), V.G. Mikity arrived at a conclusion that the syndrome he described in 1960 in cooperation with M.G. Wilson has nothing in common with BPD as far back as in 1973 [28]. Thus, the given data contradict opinion of J.E. Hodgman, who considered the “new” BPD and WMS one and the same disease [29].

Respiratory function analysis in WMS patients revealed high CO₂ content in lungs, intrapulmonary left-to-right shunt in the event of pulmonary hypertension development, pulmonary distensibility reduction due to high airway resistance, functional residual capacity reduction, air retention in lungs and high breathing-associated energy expenditure [6, 10, 15]. Pulmonary heart development is accompanied by increase in the resistance of pulmonary vessels [25, 26].

T. Takami et al. analyzed the change in the levels of sialyl carbohydrate antigen KL-6 (Krebs von den Lungen-6), surfactant protein D (SP-D) and lactate dehydrogenase (LDH) in an infant with WMS. In that case the serum KL-6 level correlated with clinical symptoms more than the levels of serum SP-D and LDH [30]. Biomarker KL-6 is a high molecular glycoprotein, a component of the mucin released by type II alveolar cells. KL-6 level is especially high in the infants with the diseases associated with congenital surfactant protein deficit [31] and the adults with various types of interstitial pneumonia, at sarcoidosis, tuberculosis etc., whereas this level does not become any higher in the event of non-interstitial pulmonary diseases (bacterial pneumonias) and neuroendocrine hyperplasia of infancy [32]. This serum marker is believed to reflect the alveolar damage at interstitial pneumonia and pulmonary fibrosis. The upper normal limit of serum markers KL-6 in adults is 500 ea/ml. T. Ogiwara et al. demonstrated that KL-6 is a reliable BPD indicator in neonates. Their study revealed that the serum KL-6 level was higher in the children with BPD than in the children without BPD from 0 to 1, 10 and 30 days of age; the average level increased considerably and exceeded 300 ea/ml in the 10th day [33].

The range of diseases to be ruled out at differential WMS diagnostics is rather extensive. In their first description of the disease, M.G. Wilson and V.G. Mikity reported that what they observed resembled the so called interstitial plasmacytic (in modern terms – pneumocystic) pneumonia, although histological examination allowed ruling that disease out. In two infants, however, histologic pulmonary alterations resembled Hamman-Rich syndrome [1]: the observations revealed apparent regression of clinical and radiographic symptoms at WMS (not typical of Hamman-Rich syndrome). Having conducted radiographic examination, it is the first priority task to determine whether the observed disease is WMS or BPD. Despite similarity of radiographic patterns and immaturity of the affected children, WMS and BPD have completely different clinical patterns. Time of manifestation, disease course and absence of mechanical ventilation rule out the possibility of BPD. Other diseases that might be included in the differential WMS diagnosis are aspiration and listeria pneumonia, histiocytosis X and pulmonary hemorrhage [1, 4].

WMS treatment is symptomatic. Oxygen therapy is performed to attenuate hypoxia. Digitalization is indicated in the event of congestive cardiac failure. Antibiotics do not affect the course of the disease; their use is reasonable only in the event of a concurrent infection. Glucocorticosteroids are not indicated for this disease as well: their preventative effect against development of fibrosis is considered to be rather doubtful [34].

Prognosis of this disease depends on many factors. The symptoms may persist for months. Pulmonary function examination reveals damage of small airways, which may persist until the age of 8-10 years. The first postnatal year is characterized by high risk of respiratory infections [34]. Several reports mention a concurrent neurological pathology in children with WMS (spastic quadriplegia, nystagmus, hydrocephalus) [3, 14]. Moreover, most patients with WMS in modern conditions require home oxygen therapy [12]. Although patients usually recover from the

pulmonary disease, fatal outcome may occur due to cardiac or respiratory failure or an infection [34]. According to A. Hoepker et al., the WMS mortality rate is 11.1% [12]. Thus, WMS remains a disease with severe prognosis, although the mortality rate has reduced in comparison to the reviews by P.R. Swyer and J.E. Hodgman featuring mortality rates of 54.5 and 35.3%, respectively [6, 14].

We observed 6 children with WMS: 3 boys and 3 girls of 27-32 weeks of GA (average GA – 29.5 ± 2.5 weeks) and birth weight of 950-1,510 g ($1,222.5 \pm 275.4$). Neonatal RDS, pneumonia or no respiratory symptoms before WMS manifestation were diagnosed in neonatology in 3, 1 and 2 children, respectively. The children did not have oxygen dependence and did not undergo APV in the first 3 weeks; 3 children received nasal continuous positive airway pressure (NCPAP). Deterioration in the condition in the form of intensification of respiratory failure symptoms, dyspnea characterized by retraction of retractable sternal areas, cyanosis, small bubbling pulmonary rales and sibilant rales was observed at the age of 24-35 (29 ± 3) days. Apnea was registered in all children (tb. 2). Chest radiography revealed moderate hyperinflation and interstitial alterations in superior lobes of pulmonary fields (cords alternating with hyperinflated pulmonary tissue areas). No inflammatory infiltration or acute inflammatory alterations were observed in X-ray films and clinical and biochemical blood analyses, respectively. Due to the development of respiratory failure, the children required oxygen therapy with an oxygen mask (2 children), an oxygen tent (3 children) or APV (1 child). Oxygen dependence resolves in children with WMS by the age of 45-54 (48 ± 7) days. After discharge from the hospital following the II developmental care stage one girl was rehospitalized due to an apnea episode, which required a 17-day-long APV. We did not observe any respiratory issues in the follow-up of the other 5 children with WMS until 2 years of age; chest radiograms normalized. One of the observed WMS patients underwent pulmonary HRCT.

Case study

Boy K. was admitted to the resuscitation and intensive care unit of the children's infectious diseases clinical hospital No. 6 of the Department of Healthcare of Moscow on 07.05.2013 at the age of 9 days with guiding diagnosis "Intrauterine conjunctivitis, hypoxic-ischemic lesion of the central nervous system (suppression syndrome), prematurity (30 weeks), intrauterine growth retardation, conjugated jaundice, anemia, inconclusive HIV test". Anamnesis revealed that the child's mother was 31 years of age with burdened infectious (HIV infection, chronic hepatitis C, syphilis (since 2000), chronic genital candidiasis), somatic (smoking, drug addiction) and obstetric-gynecological (chronic salpingitis) histories. This 9th pregnancy (3rd-5th pregnancies were terminated with therapeutic abortions; the 8th pregnancy resulted in missed miscarriage) was characterized by toxicosis and chlamydia infection (received treatment) in trimester I; trimester II was characterized by genital candidiasis exacerbation and an acute respiratory viral infection; trimester III – by anemia and acute laryngitis. The labor was the 5th, preterm (in the 30th-31st gestational week) and operative (incomplete placenta previa) and prenatal amniorrhea. Latency period – 26 hours. Bright amniotic fluid. Birth weight – 1,500 g. Apgar score – 7/8. Condition at birth – severe due to neonatal RDS and pathological neurological symptoms. RDS terminated by the 3rd postnatal day. Conjunctivitis and conjugated jaundice appeared at the same time.

No clinical symptoms of respiratory failure or lower respiratory tract lesion were observed at admission. Oxygen therapy was not necessary. Auscultation of the lungs revealed diminished breath sounds on both sides. Negative dynamics, aggravation characterized by development of oxygen dependence at the age of 25 days and O₂ saturation of 86-88% without supplemental oxygen were observed in the course of inpatient treatment. Oxygenation was performed using an oxygen tent. Mixed dyspnea characterized by retraction of retractable sternal areas (intercostal spaces) in the lower segments aggravating at exertion, tachypnea with respiratory rate of up to 60 respiratory movements per minute, cyanosis, chest distension, short-term apnea episodes and

tendency to bradycardia. Auscultation of the lungs revealed diminished breath sounds and no rales. Clinical symptoms of infectious process and blood inflammatory alterations were not observed.

Chest radiography performed at the age of 25 days revealed uneven pulmonary tissue transparency decline, enrichment and glomerular deformation of vascular pattern; bilateral diffuse stripe-like infiltration of pulmonary tissue coming from roots of the lungs and located primarily in the superior lobes and hyperaeration of inferior lobes were observed (pic. 1). Regularly performed radiographic examinations revealed increase in interstitial alterations. Chest HRCT at the age of 7 weeks performed due to persistence of lower respiratory tract lesion symptoms, respiratory failure and oxygen dependence visualized alterations, which were strikingly similar to the alterations described by P. Reittner et al. [13]: pronounced deformation of vascular pattern, rough peribronchovascular and interlobar interstitial thickening, numerous lobular traction inflations, rough fibrotic fold; unremarkable trachea, permeable undeformed 1st-3rd-order bronchi (pic. 2). Thus, pulmonary and bronchial malformations and pneumonia were ruled out. Clinical and biochemical blood analyses revealed no deviations. Serologic tests for HIV, mycoplasmosis, chlamydia infection, herpetic and cytomegalovirus infection were negative.

The child's condition gradually improved; respiratory failure attenuated; apnea and bradycardia tendency disappeared. The boy was discharged from the hospital at the age of 2 months; the follow-up observation revealed pronounced positive dynamics (O₂ saturation – 98%).

In this case, results of radiographic examinations allowed confirming diagnosis of WMS diagnosis in the premature infant with burdened perinatal anamnesis, resolved neonatal RDS, respiratory failure manifestation, lower respiratory tract lesion characterized by development of oxygen dependence at the age of 25 days (later resolved). Complex examination allowed ruling out pneumonia, tracheobronchial tree and pulmonary malformations and perinatal infections. Time of manifestation of oxygen dependence and absence of APV allowed ruling out BPD. This case was remarkable for development of WMS in a premature infant with neonatal RDS in the past medical history – one cause of respiratory failure (neonatal RDS) was substituted by another (WMS). Prematurity, neonatal RDS and oxygen dependence in neonatality are not contradictory to the WMS diagnosis.

Thus, WMS is a rare interstitial pulmonary disease observed in neonates requiring differential diagnostics with BPD, pneumonia and a range of other diseases. WMS course has become more favorable in the present conditions.

Table 1. Clinical anamnestic description of WMS patients and outcomes [1, 3, 9, 12, 14, 15, 20-25]

Descriptor		Rate, abs. (%) n = 61
Birth weight (g)	500-999	14 (23)
	1,000-1,499	33 (54)
	1,500-2,499	13 (21)
	2,500-4,000	1 (2)
Sex	Boys	37 (61)
	Girls	24 (39)
Gestational age (weeks)	24-28	26 (43)
	29-33	21 (34)
	34-37	6 (10)
	38-42	1 (2)
	N/A	7 (11)
Age at clinical manifestation (postnatal days)	1-10	23 (38)
	11-20	15 (25)
	21-30	19 (31)

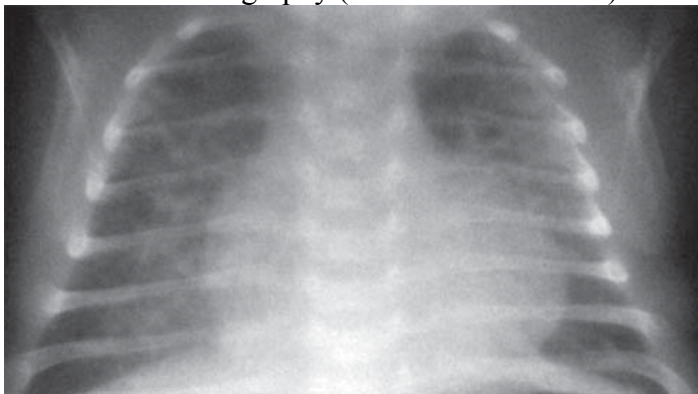
	> 30	4 (6)
Outcomes	Fatal	19 (31)
	Recovery	35 (58)
	N/A	7 (11)

Table 2. Clinical anamnestic description of WMS patients (authors' own data)

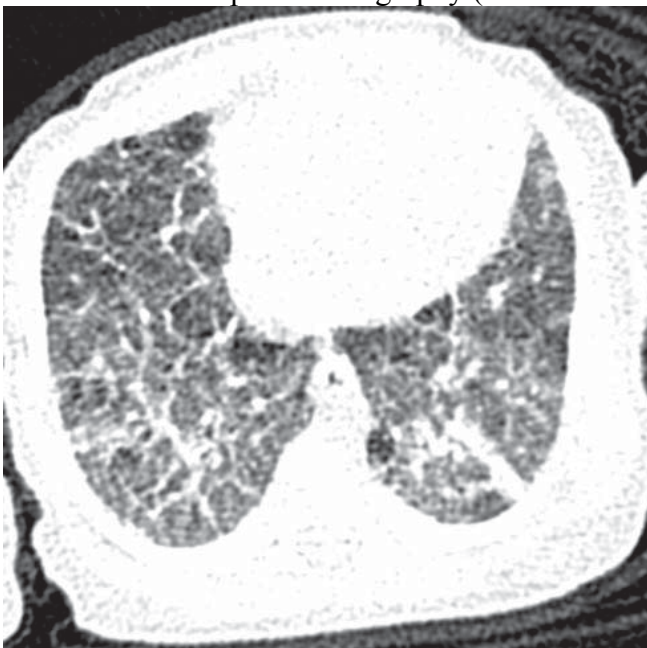Case	Birth weight	Sex	GA (weeks)	Initial respiratory support		Age at manifestation (days)
				APV	NCPAP	
1	1,030	F	28	-	+	33
2	1,500	M	30	-	-	24
3	1,430	F	32	-	+	35
4	950	F	27	-	+	24
5	1,000	M	27	-	-	31
6	1,510	M	31	-	-	32

Note. GA – gestational age, APV – artificial pulmonary ventilation, NCPAP – nasal continuous positive airway pressure.

Pic. 1. Chest radiography (described in the text)



Pic. 2. Chest computed tomography (described in the text)



REFERENCES

1. Wilson M. G., Mikity V. G. A New Form of Respiratory Disease in Premature Infants. *Am J Dis Child*. 1960; 99: 489–499.
2. Butterfield J., Moscovici C., Berry C., Kempe C. H. Cystic emphysema in premature infants. *New Eng J Med*. 1963; 268: 18–21.
3. Baghdassarian O. M., Avery M. E., Neuhauser E. B. D. A form of pulmonary insufficiency in premature infants. *Amer J Roentgen*. 1963; 89: 1020–1031.
4. Grossman H., Berdon W. E., Mizrahi A., Baker D. H. Neonatal focal hyperaeration of the lungs (Wilson-Mikity syndrome). *Radiology*. 1965; 85: 409–417.
5. Kaufmann H. J. A new form of fibrosis of the lung in premature babies. *Fortschr Röntgenstr*. 1962; 97: 434–440.
6. Swyer P. R., Delivoria-Papadopoulos M., Levinson H. et al. The pulmonary syndrome of Wilson and Mikity. *Pediatrics*. 1965; 36: 374–381.
7. Burnard E. D., Grattan-Smith P., Picton-Warlow C. G., Grauaug A. Pulmonary insufficiency in prematurity. *Aust Paediat J*. 1965; 1: 12–36.
8. Bucci G., Iannaccone G., Scalamandre A. et al. Observations on the Wilson-Mikity syndrome. *Ann Paediat*. 1966; 206: 135–149.
9. Sinnette C. H., Bradley-Moore A. M., Cockshott W. P., Edington G. M. Wilson-Mikity respiratory distress syndrome. *Arch Dis Child*. 1967; 42: 85–90.
10. Aherne W. A., Cross K. W., Hey E. N., Lewis S. R. Lung function and pathology in a premature infant with chronic pulmonary insufficiency (Wilson-Mikity syndrome). *Pediatrics*. 1967; 40: 962–974.
11. Baklanova V.F., Vladykina M.I. *Rukovodstvo po rentgenodiagnostike boleznei organov dykhaniya u detei* [Guideline on Radiodiagnosis of Respiratory Diseases in Children]. Leningrad, Medicine, 1978. pp. 147-150.
12. Hoepker A., Seear M., Petrocheilou A. et al. Wilson–Mikity Syndrome: Updated Diagnostic Criteria Based on Nine Cases and a Review of the Literature. *Pediatric Pulmonology*. 2008; 43: 1004–1012.
13. Reittner P., Fötter R., Tillich M. et al. High-resolution CT findings in Wilson-Mikity syndrome: a case report. *Pediat Radiol*. 1998; 28: 691–3.
14. Hodgman J. E., Mikity V. G., Tatter D., Cleland R. S. Chronic respiratory distress in the premature infant. Wilson-Mikity syndrome. *Pediatrics*. 1969; 44 (2): 179–195.
15. Saunders R. A., Milner A. D., Hopkin I. E. Longitudinal studies of infants with the Wilson-Mikity syndrome. *Biol Neonate*. 1978; 33 (1–2): 90–99.
16. Fujimura M., Takeuchi T., Ando M. et al. Elevated immunoglobulin M levels in low birth-weight neonates with chronic respiratory insufficiency. *Early Hum Dev*. 1983; 9 (1): 27–32.
17. Jobe A. H., Kallapur S. G., Kramer B. W. Perinatal events and their influence on lung development and function. Experimental Chronic Chorioamnionitis. In: Bancalari E., Polin R. A., eds. *Newborn Lung: Neonatology Questions and Controversies*. WB Saunders Co Pub, 2008. pp. 75–76.
18. Fujimura M., Kitajima H., Nakayama M. Increased leukocyte elastase of the tracheal aspirate at birth and neonatal pulmonary emphysema. *Pediatrics*. 1993; 92 (4): 564–9.
19. Ovsyannikov D.Yu. *Voprosi prakticheskoi pediatrii - Problems of practical pediatrics*. 2008; 3(5): 97–102.
20. Ibrahim J. M., Russell A. Late Prolonged Respiratory Distress Syndrome. *Proc R Soc Med*. 1966; 59 (6): 487–9.
21. Keidel W. N., Feingold L. M. Wilson-Mikity syndrome in a full-term male twin. *Pediatrics*. 1971; 47 (4): 779–81.
22. Lehman D. H. The Wilson-Mikity Syndrome — Case Report and Review of Literature. *Calif Med*. 1969; 111 (4): 298–304.
23. Cooperman E. M. Wilson-Mikity syndrome (pulmonary dysmaturity syndrome). *Can Med Assoc J*. 1969; 100 (19): 909–912.

24. Sotnikova K.A., Panov N.A. *Pnevmonii i pnevmopatii novorozhdennykh detei* [Pneumonia and Pneumopathies in Premature]. Moscow, Meditsina, 1975. pp. 74–79.
25. Krauss A. N., Levin A. R., Grossman H., Auld P. A. Physiologic studies on infants with Wilson-Mikity syndrome. Ventilation-perfusion abnormalities and cardiac catheterization angiography. *J Pediatr.* 1970; 77 (1): 27–36.
26. Grossman H., Levin A. R., Winchester P. H., Auld P. A. Pulmonary hypertension in the Wilson-Mikity syndrome. *Am J Roentgenol Radium Ther Nucl Med.* 1972; 114 (2): 293–299.
27. Bratanov B.R. *Klinicheskaya pediatriya. Tom 1* [Clinical Pediatrics. Volume 1]. St. Petersburg, Sofiya, Meditsina i fizkul'tura, 1987. 69 p.
28. Mikity V. G., Taber P. Bronchopulmonary dysplasia oxygen toxicity and the Wilson-Mikity syndrom. *Pediatr Clin N Am.* 1973; 2: 419–31.
29. Hodgman J. E. Relationship between Wilson-Mikity syndrome and the new bronchopulmonary dysplasia. *Pediatrics.* 2003; 112: 1414–5.
30. Takami T., Kumada A., Takei Y. et al. A case of Wilson-Mikity syndrome with high serum KL-6 levels. *J Perinatol.* 2003; 23 (1): 56–8.
31. Ovsyannikov D.Yu., Belyashova M.A., Krushel'nitskii A.A. etc. *Voprosy diagnostiki v pediatrii – Diagnostics in pediatrics.* 2013; 5(1): 12–20.
32. Ovsyannikov D.Yu., Belyashova M.A., Zaitseva N.O. etc. *Pediatriya – Pediatrics.* 2013; 3: 32–37.
33. Ogihara T., Hirano K., Morinobu T. et al. Plasma KL-6 predicts the development and outcome of bronchopulmonary dysplasia. *Pediatr Res.* 2006; 60 (5): 613–8.
34. Sosenko I.R.S., Bancalari E., Greenough A. Bronchopulmonary dysplasia. In: Greenough A., Milner A. D., eds. *Neonatal Respiratory Disorders.* 2th ed. London, Hodder Arnold. 2003. pp. 415–422.