

E.N. Basargina, E.N. Arkhipova, V.S. Ermolenko

Scientific Center of Children's Health, Moscow, Russian Federation

Alglucosidase alfa – a new stage in the therapy of infantile Pompe disease

Author Affiliation:

Elena Nikolayevna Basargina, MD, PhD, Professor, head of the cardiovascular care unit at the research institute of pediatrics of the Scientific Center of Children's Health (Federal State Budgetary Research Institution)

Address: 2/1 Lomonosovskiy Av., Moscow, 119991; **tel.:** +7 (499) 134-04-90;

e-mail: basargina@nczd.ru

Article received: 04.08.2014. Accepted for publication: 17.09.2014.

Pompe disease is a rare severe hereditary disease caused by excessive glycogen storage in organs and target tissues due to the acid α -glucosidase gene mutation. Infantile and adult Pompe disease is characterized by involvement of cardiovascular, respiratory and muscular systems in the pathological process. The only specific method of treating Pompe disease is enzyme replacement therapy (intravenous administration of recombinant human acid glucosidase), the effectiveness whereof depends on the time the therapy started. Since such a therapy was introduced into practice, Pompe disease mortality decreased by 79%. 6 children with infantile Pompe disease were observed and treated at the cardiovascular care unit of the Scientific Center of Children's Health in 2011-2014. The article presents a clinical case demonstrating capabilities of diagnosing infantile Pompe disease in Russia and effective application of alglucosidase alfa in 4-month-old child.

Keywords: Pompe disease, storage disease, infantile disease, enzyme replacement therapy.

INTRODUCTION

Pompe disease is an autosomal-recessive hereditary disease; the gene thereof is mapped to chromosome 17q25. There are more than 300 known mutations of this gene. Incidence of this pathology in Russia is unknown; only singular cases are registered. This may probably result from insufficient knowledge of medical practitioners. The summary incidence of all the disease forms is 1:40,000 [1].

Gene *GAA* mutation results in the acid alpha-glucosidase enzyme defect, failure of glycogen breakdown and the storage thereof in lysosomes and myocardial cytoplasm (contractile and conduction systems), skeletal muscles and liver; this leads to irreversible damage to the ill person's organs and tissues and defines clinical pattern of Pompe disease (type IIa glycogenosis) [2].

Forms and clinical course of Pompe disease

Pompe disease is characterized by progressive course. Clinicians distinguish between infantile and adult forms; infantile form is associated with rapid fatal outcome in the first year of life; adult form – with slow persistent aggravation of the ill person's condition and/or premature death.

Infantile form. Clinical manifestations usually occur in the first months of life. Condition severity is caused by a number of pathological alterations. All children are characterized by arrested motor development and loss of the acquired skills. Severe rapidly progressing hypotonia develops concurrently (floppy baby syndrome, head lag). Despite myasthenia, gastrocnemius muscles appear hypertrophied and firm on palpation. Difficulties associated with feeding and swallowing are aggravated by macroglossia and insufficient weight gain.

The disease is characterized by disturbed (especially sleep-disturbed) breathing, respiratory failure and frequent respiratory diseases (pneumonia, bronchitis).

Malignant course of infantile Pompe disease is largely caused by the cardiovascular disorders that are rare in adults. Myocardial hypertrophy as a sign of developing hypertrophic cardiomyopathy is detected by means of ultrasonography intrauterine or in a child from the first months of life. Cardiac failure manifestations rapidly progress in children. Dyspnea, edema, hepatomegaly and cyanosis come under notice. Auscultation helps to register tachycardia, gallop rhythm and rasping systolic murmur caused by obstructed ventricular outflow track. Frequent aspiration pneumonias further cardiac failure progression.

Infantile Pompe disease untreated with enzyme replacement therapy (ERT) results in fatal outcome due to cardiac and cardiopulmonary failure; according to the literature, the average age at death is 8.7 months [3].

Adult form. Pompe disease symptoms may occur at any age; the most prominent of them are proximal myasthenia, gait disorder, myalgia, difficulty stair climbing and frequent falls. The disease usually manifests itself with progressive pelvic and spinal myasthenia. Pulmonary hypertension symptoms and right ventricular failure aggravating at night may develop due to hypoventilation caused by progressive neuromuscular diaphragm disorder. The disease is characterized by orthopnea, dyspnea in the event of exercise stress, respiratory infections, diurnal drowsiness, morning headache, nocturnal hypoventilation and respiratory failure in the absence of cardiomegaly. Difficulty chewing or maxillary myasthenia complicates feeding and swallowing and causes physical developmental delay and weight loss. Unlike the infantile form, the adult form is observed rarely (in 30% of all the cases) and may be detected accidentally in the course of examination for myasthenia. Chronic cardiac failure develops slowly, for years and may remain latent for a long time. Hepatomegaly is observed far less often, as well as macroglossia. Premature death is caused by cardiopulmonary failure.

Diagnosis

Pompe disease diagnosis involves both detailed familial anamnesis (cases of death in infancy, myopathies etc.) and anamnesis morbi taking into account the examination data obtained in the intrauterine development period (myocardial hypertrophy, fetal cardiac rhythm disturbance). Out of the clinical manifestations, dominating myasthenia, loss of skills and/or cardiopulmonary failure and, importantly, combination of these manifestations characterized by increased blood creatine phosphokinase (CPK) and lactate dehydrogenase (LDH). The highest enzyme activity is usually observed at infantile Pompe disease (up to 2,000 IU/l).

The doctor's further actions ought to concern the patient's examination by consultants (cardiologist, neurologist etc.) in order to identify any potential causes of the detected clinical disorders. The following instrumental examinations are required: echocardiogram (EchoCG), electrocardiogram (ECG), chest radiography, electromyography, blood assay (plasma creatine kinase, alanine and aspartate aminotransferase (ALT/AST), LDH etc.).

According to the ECG data, children with cardiomyopathy are characterized by left ventricular or biventricular myocardial hypertrophy, high QRS and T wave voltage, short P-R interval, disturbed repolarization in the form of depression or, less often, ST segment increase and symmetrical T wave inversion in leads I and II and left leads. Wolff-Parkinson-White (WPW) syndrome and I or II degree atrioventricular block may be observed at the adult form. Chest radiography registers circular-shaped heart shadow and increased pulmonary vascularity; EchoCG – myocardial hypertrophy, ventricular cavity shrinkage, signs of outflow track obstruction (hypertrophic cardiomyopathy pattern). Myocardial hypertrophy is usually concentric (symmetrical), less often – asymmetrical, with primary interventricular septal hypertrophy. Asymmetrical septal hypertrophy is often characterized by the mitral valve leaflet's anterior systolic motion; dopplerography registers an aorta-LV (left ventricle) pressure gradient. Along with left ventricular hypertrophy, the infantile form is often characterized by hypertrophy of the free right ventricular wall and increased contractility thereof.

It is important to evaluate the acid alpha-glucosidase (GAA) enzyme activity in order to confirm the diagnosis. Skin fibroblast culture (SFC), biopsy samples of muscles or liver were previously used as the biological material. Now, minimally invasive dry blood tests are performed to determine the enzyme's quantitative activity [4]. A molecular genetic examination is performed in the event of GAA decrease in order to identify a mutation in the acid maltase gene, as well as to assess carriage (family/sibs). Mutation identification may also serve a prognostic purpose.

Differential diagnosis

- Myopathies.
- Central nervous system diseases (limb-girdle myopathy, Duchenne and Becker myodystrophies, spinal amyotrophy, polymyositis).
- Danon disease (type IIb glycogenosis).
- Cardiomyopathies of different etiology.

Prognosis

Depends on age at disease manifestation and ERT beginning.

Treatment

For a long time, healthcare provision to patients with Pompe disease was limited to symptomatic measures aimed at arresting manifestations of cardiopulmonary failure [diuretics, β -blockers, angiotensin-converting enzyme inhibitors, artificial pulmonary ventilation (APV), tracheostomy] and myopathic syndrome (exercise therapy, massage, gymnastics). Such a therapy would only temporarily improve the quality of life, but it could not change the disease course.

The only specific method of treating Pompe disease is the ERT aimed directly at the primary metabolic defect. Now, pathogenetic ERT may be performed by means of intravenous administration of recombinant human acid glucosidase (alglucosidase alfa, Myozyme, Genzyme, Belgium), which compensates for the missing or insufficient enzyme and, as acid alpha glucosidase, breaks glycogen down to glucose [3, 5]. Alglucosidase alfa is a recombinant human acid α -glucosidase rDNA-produced (recombinant) using Chinese hamster ovary cell culture. It has been established that alglucosidase alfa compensates for lysosomal acid α -glucosidase activity; this leads to stabilization or recovery of function of heart and skeletal muscles (including respiratory muscles). Treatment with alglucosidase alfa must be performed under supervision by a doctor experienced in working with patients with Pompe disease or other hereditary metabolic or neuromuscular diseases.

Clinical studies of patients with infantile Pompe disease demonstrated that pharmacokinetic properties of alglucosidase alfa are proportional to the dose and do not change with time. The mean maximum drug concentration in plasma (C_{max}) after the first and the sixth infusions varied from 178.2 to 263.7 mcg/ml, the mean area under the concentration-time curve (AUC) – from 977.5 to 1,872.5 mcg*h/ml. The mean plasma clearance (CL) was 21.4 ml/kg per hour, the mean steady state volume of distribution (V_{ss}) – 66.2 ml/kg. The mean plasma elimination half-life ($t_{1/2}$) is 2.75 hours. The recommended alglucosidase alfa dosing schedule is 20 mg/kg of body weight BIW via intravenous infusions with gradual increase in drug infusion rate [6].

ERT effectiveness depends on the disease form and stage: it is important to start treatment as early as possible to achieve the best results. The most favorable results at the infantile form of the disease were achieved when therapy had been started at a young age, before skeletal muscles could be damaged significantly. ERT effectiveness is significantly lower at later stages of the disease, when widespread vacuolation and interstitial tissue replacement lead to irreversible damage of myofibers and tissue structure, although certain improvement in motor and respiratory function may be achieved even if treatment starts late [7]. Some patients demonstrate significant clinical improvement, other – only minimal response to the therapy. ERT results in infants with Pompe disease are characterized:

- by increased lifespan and decreased need in APV;

- by treatment or prevention of the life-threatening disease manifestations;
- by acquisition of new motor skills;
- by increase in or maintenance of growth parameters within the age norm.

Decreased need in APV, increased forced lung capacity, increased mobility and walkability, recovery of motor skills, increase in body weight in accordance with the age norm and life quality improvement are observed in older children and adults.

According to a clinical study of 21 children (3-43 months of age, median – 13 months), 44% of the patients treated with ERT did not require invasive respiratory support, 62% - acquired new motor skills; left ventricular mass index decreased in 100% of the patients. In comparison with the retrospective cohort of the patients who did not receive specific treatment, death risk decreased by 79% ($p < 0.001$), invasive pulmonary ventilation risk – by 58% ($p < 0.02$) [2]. Early ERT start (before the age of 6 months) at infantile Pompe disease was more effective than specific therapy start at the age of 6-36 months. Thus, the survival rate within 1 year was 100 and 73%; invasive respiratory support was not required in 83 and 50% of the cases; left ventricular mass index decrease was observed in 100 and 87% of the cases, recovery and development of motor skills – in 72 and 40% of the cases, respectively [8].

In the Russian Federation the enzyme replacement drug recommended for Pompe disease has not been registered; however, as this approach is the only specific method of treating this severe disease, ERT is utilized in critical situations.

6 children (4 boys, 2 girls) with infantile Pompe disease were observed and treated at the cardiology unit of the Scientific Center of Children's Health in 2011-2014; they were among the first patients in Russia to undergo ERT by means of intravenous administration of recombinant human acid glucosidase (alglucosidase alfa). 3 children are still being observed.

Below we provide a case study.

CLINICAL CASE

Child E. of the 2nd and uncomplicated pregnancy. Routine fetal ultrasonography at gestational week 22-23 detected cardiac wall hypertrophy. Timely spontaneous vaginal delivery. EchoCG at the age of 5 days demonstrated remaining signs of myocardial hypertrophy (posterior left ventricular wall [PLVW] – 5.5 mm, interventricular septum [IVS] – 5.7 mm); ECG: disturbed myocardial repolarization, myocardial hypertrophy. Local doctors interpreted these cardiac alterations as postmyocarditis myocardial hypertrophy.

The mother observed appearance and intensification of nasolabial triangle cyanosis, atony and loss skills (the girl ceased to control head and grasp toys) at the child's age of 1.5 months. The follow-up EchoCG demonstrated rapid intensification of left ventricular wall hypertrophy (PVLW – 9 mm, IVS – 12 mm).

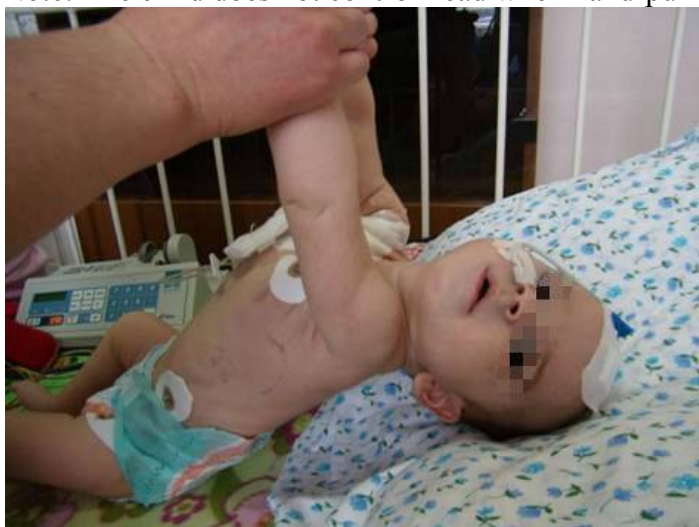At the age of 3 months the child diagnosed with hypertrophic cardiomyopathy in severe condition was admitted to the cardiology unit of the Scientific Center of Children's Health (Federal State Budgetary Research Institution) for the first time. The following aspects came under notice at examination: 3rd degree hypertrophy, macroglossia, nasolabial triangle cyanosis, hyperhidrosis, peripheral edema, grunting breathing, pronounced cardiac hump, hepatomegaly; percussion: cardiac border extension, muffled heart sounds, tachycardia (up to 190/min.), harsh respiration (involving subsidiary muscles), tachypnea (up to 60/min.), oxygen saturation – 82%. No head control, weak sucking, choking, weak cry (pic. 1).

EchoCG: pronounced cardiac wall hypertrophy (PLVW – 13 mm, IVS – 15 mm) and the left ventricular ejection fraction decrease down to 27% confirmed by signs of left heart overload identified by ECG (pic. 2A, 3).

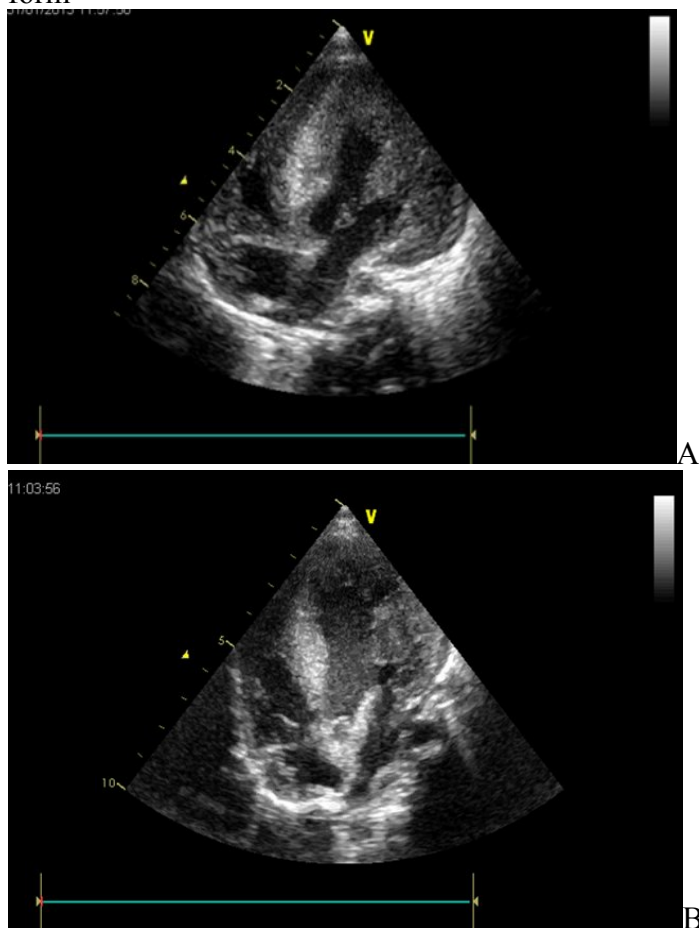
Chest radiography (anteroposterior view): cardiomegaly, cardiothoracic index – 78% (pic. 4A).

Biochemical blood assay: ALT – 153 U/l, AST – 288 U/l, LDH – 1,410 U/l, CPK – 1,582 U/l, CPK-MB – 19.1 ng/ml, NT-proBNP – 17,859 gp/ml.

Pic. 1. Patient E., 3 months of age. Diagnosis: “Pompe disease, infantile form”
Note. The child does not control head when hand-pulled.



Pic. 2. Echocardiogram (4-chamber view) of patient E. Diagnosis: “Pompe disease, infantile form”

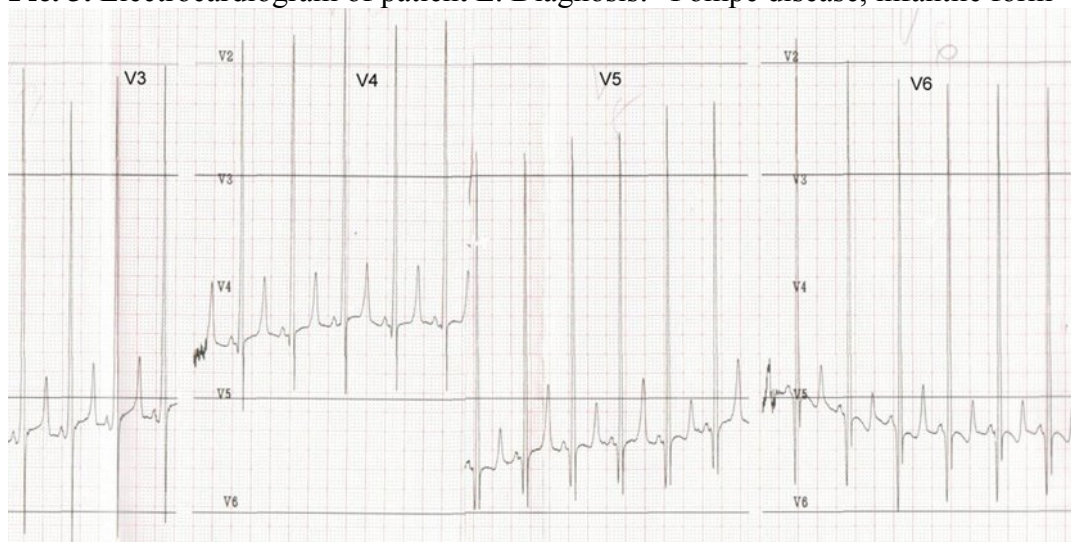


Note.

A (at admission): IVS – 17 mm, PLVW – 15 mm (January 2013).

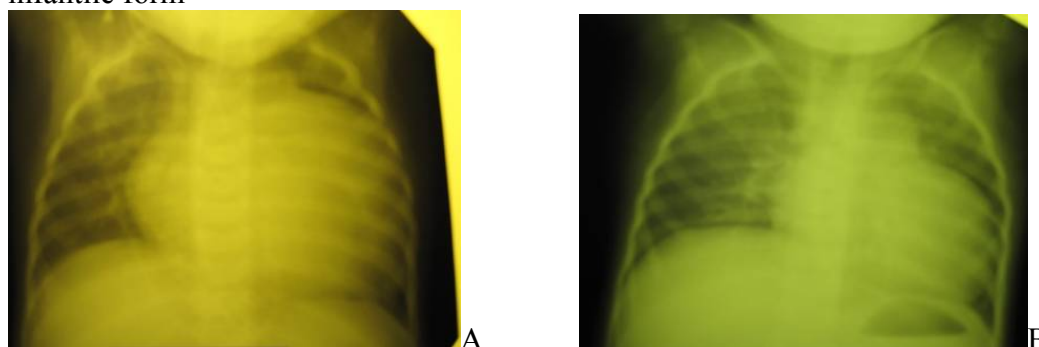
B (after 20 ERT infusions): IVS – 11 mm, PLVW – 12 mm (November 2013).

Pic. 3. Electrocardiogram of patient E. Diagnosis: “Pompe disease, infantile form”



Signs of overload of the left heart myocardium overload and, possibly, of the right ventricle.

Pic. 4. Chest radiogram (anteroposterior projection) of patient E. Diagnosis: “Pompe disease, infantile form”



Note. Pronounced cardiomegaly. Enlargement of the left and the right heart.

A (at admission): cardiothoracic index – 78% (January 2013).

B (after 20 ERT infusions): cardiothoracic index – 60% (November 2013).

Examination data

Given clinical pattern of the disease and the alterations identified by means of laboratory and instrumental diagnosis, we suspected infantile Pompe disease. In order to confirm the diagnosis we determined blood alpha-D-glucosidase activity; the enzyme speed was 2.2 nM/mg per hour. DNA diagnosis demonstrated mutation of segment c.875>T of gene *GAA* (the examination was performed at molecular genetic diagnostic laboratory of the Scientific Center of Children's Health [Federal State Budgetary Research Institution]). Diagnosis of Pompe disease was confirmed.

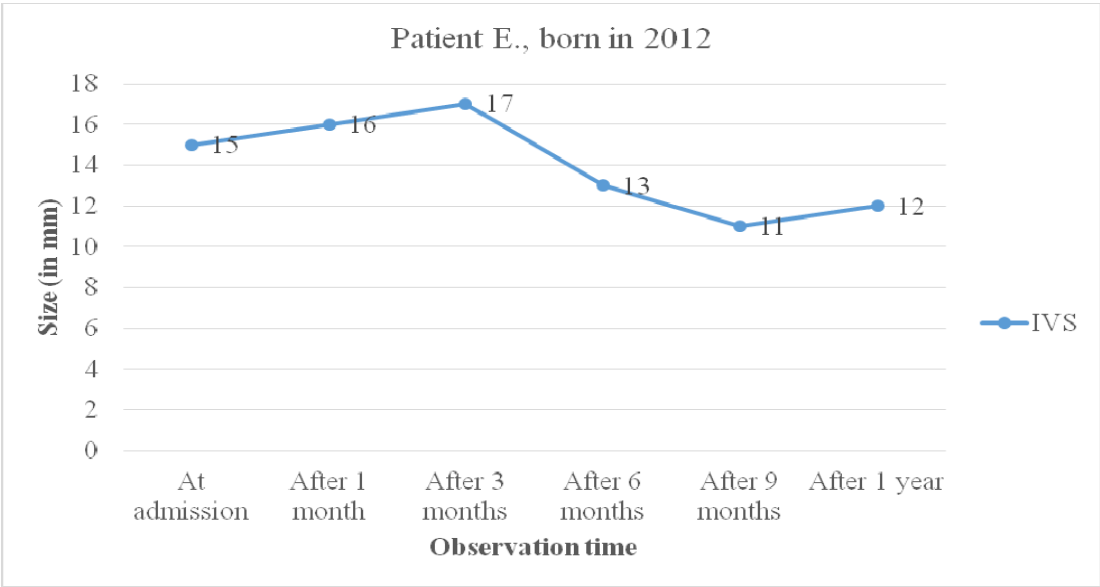
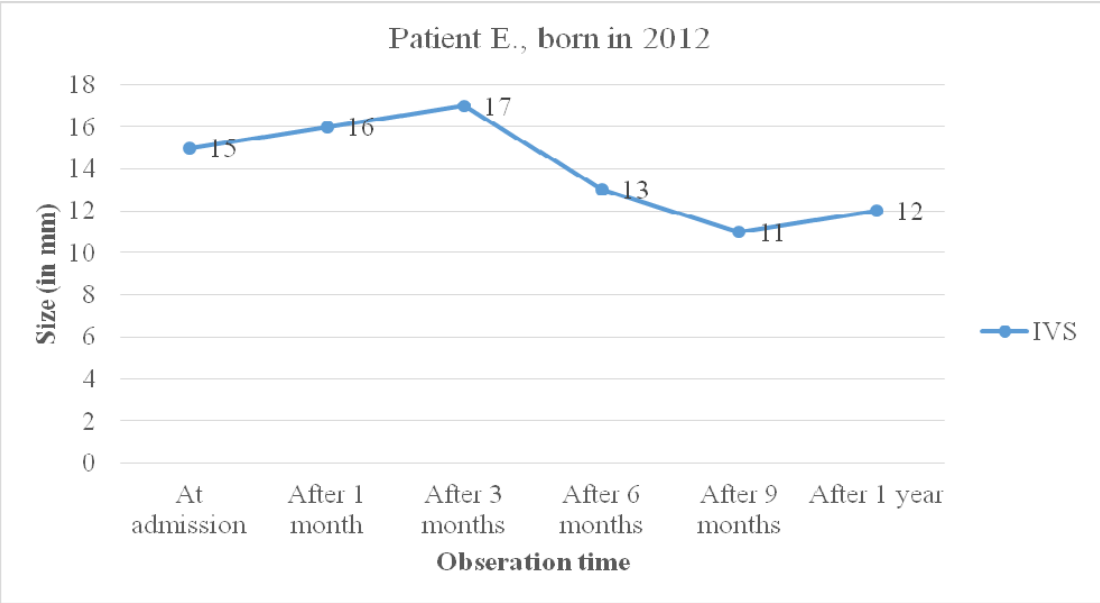
ERT with 20 alglucosidase alfa mg/kg for 14 consecutive days was started at the age of 4 months; cardiac failure correction (diuretics, antiarrhythmic drugs, angiotensin-converting enzyme inhibitors, β -blockers) was performed concurrently. Sanitation of nasopharynx and upper airways was performed frequently in order to suppress and prevent pulmonary engorgement; the child underwent courses of massage and exercise therapy, as well as physiotherapeutic procedures. A nasogastral tube was used for feeding with high-calorie

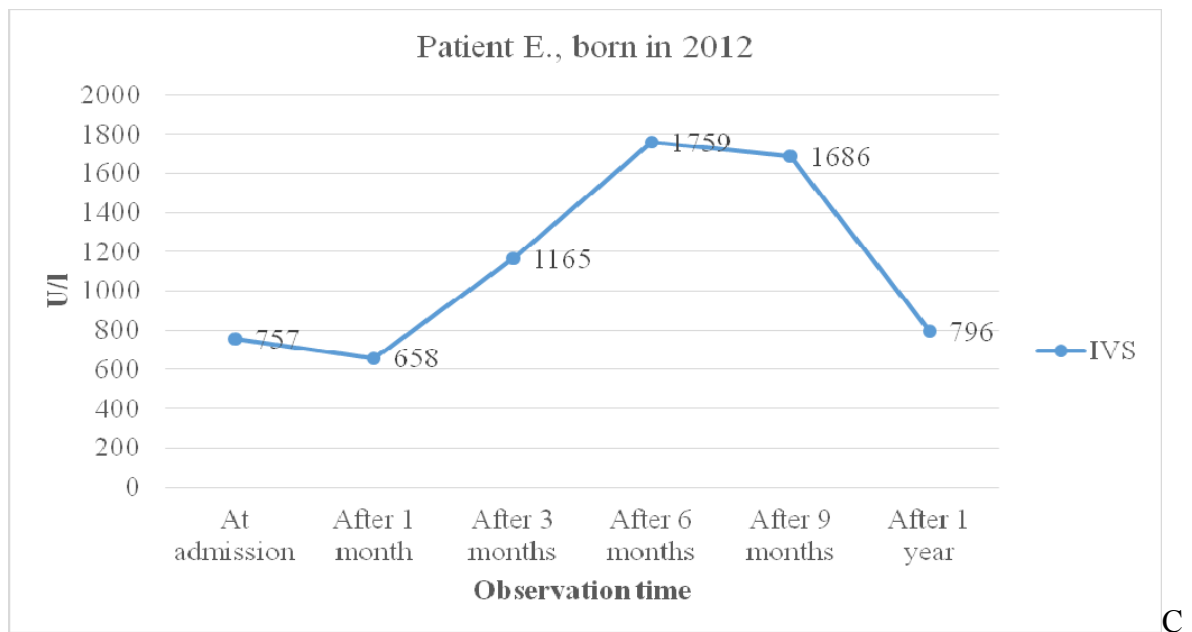
formulae in order to prevent aspiration and taking into consideration pronounced hypertrophy caused by dysphagia.

Positive dynamics in the form of the left ventricular ejection fraction increase up to 53%, left ventricular myocardial wall thickness decrease (PLVW – 12 mm, IVS – 11 mm), cardiothoracic index decrease down to 60% (chest radiography, pic. 4B) and brain natriuretic hormone (NT-proBNP) decrease down to 1,200 pg/ml was observed in the setting of the mixed treatment (20 alglucosidase alfa infusions). Dynamics of left ventricular myocardial thickness and plasma concentration of NT-proBNP and CPK is given in pic. 5.

The first results of the 6-months-long specific treatment demonstrated psychomotor development improvement: higher muscle tone and motor activity of the child. The girl is keenly interested in toys, holds them for long periods of time, started to turn over and control head (pic. 6). Biochemical parameters did not change significantly.

Pic. 5. Patient E. Diagnosis: “Pompe disease, infantile form”



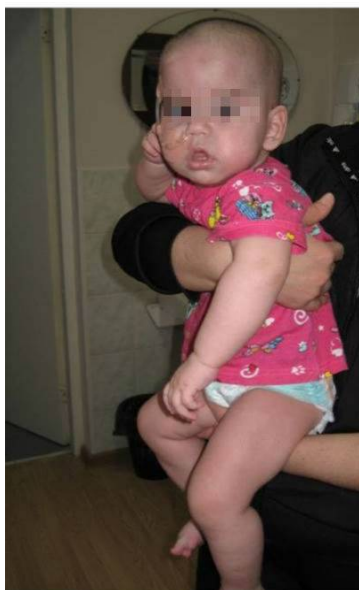

Note. Dynamics of parameters.

A – posterior left ventricular myocardial wall thickness; B – plasma NT-proBNP; C – plasma CPK; IVS – interventricular septum; CPK – creatine phosphokinase.

Pic. 6. Child E., 1 year of age. Diagnosis: “Pompe disease, infantile form”

Note. The child started to control head in the setting of the enzyme replacement therapy (20 infusions).



DISCUSSION

The given clinical case demonstrates a difficult way to diagnosis and subsequent treatment of a child. Risk of this severe pathology ought to be taken into consideration when myocardial hypertrophy is detected in a fetus or a child in the first months of age. In this case the child has been under a pediatrician's observation since birth, under a cardiologist's observation – since the age of 1.5 months; she was examined by a neuropathologist due to worsening hypotonia; however, interpretation of the detected alterations was wrong.

Taking into consideration the data of the child's examination at the Scientific Center of Children's Health, comparison of laboratory diagnostic results (increase in the concentration of transaminases and creatine phosphokinase), clinical symptoms (hypotrophy, complete absence of

motor activity, diffuse hypomyotonia, gastrocnemius muscle pseudohypertrophy, signs of cardiac and respiratory failure, macroglossia), EchoCG data (hypertrophic cardiomyopathy), as well as negative dynamics of parameters in the process of observation, Pompe disease was suspected. The girl was one of the first Russian patients to undergo ERT with alglucosidase alfa to a health-promoting effect. Lack of dynamics of biochemical parameters comes under notice: blood plasma concentration of transaminases and creatine phosphokinase remains high; this requires further analysis and explanation.

CONCLUSION

Thus, despite a vivid clinical pattern, the disease often remains unrecognized or is diagnosed too late. The need in the earliest possible diagnosis of Pompe disease is caused by availability and confirmed effectiveness of alpha-glucosidase ERT [9], which enables arresting disease progress and avoid fatal outcome at a young age [8].

CONFLICT OF INTEREST

The authors have indicated they have no financial relationships relevant to this article to disclose.

REFERENCES

1. Hirshhorn R., Reuser A. Glycogen storage disease type II: acid alpha-glucosidase (acid maltase) deficiency. In: C.R. Scriver, A.L. Beaudet, W.S. Sly, D. Valle (eds). *The metabolic and molecular bases of inherited disease*. New York: McGraw Hill. 2001. P. 3389–3420.
2. Nicolino M., Byrne B., Wraith J.E. et al. Clinical outcomes after long-term treatment with alglucosidase alfa in infants and children with advanced Pompe disease. *Genet Med*. 2009; 11 (3): 210–209.
3. Kishnani P.S., Hwu W.L., Mander H. et al. A retrospective, multinational, multicenter study on the natural history of infantile onset Pompe disease. *J Pediatrics*. 2006; 148: 671–676.
4. Umapathysivam K., Hopwood J.J., Meikle P.J. Determination of acid alpha-glucosidase activity in blood spots as a diagnostic test for Pompe disease. *Clin Chem*. 2001; 47: 1378–1383.
5. Amalfitano A., Bengur A.R., Morse R.P. et al. Recombinant human acid — glucosidase enzyme therapy for infantile glycogen storage disease type II: results of a phase I/II clinical trial. *Genet Med*. 2001; 3: 132–138.
6. Myozyme [Summary of Product Characteristics]. *Genzyme Europe BV*. 2006.
7. Angelini C., Semplicini C. Enzyme replacement therapy for Pompe disease. *Curr Neurol Neurosci Rep*. 2012; 12: 70–75.
8. Kishnani P.S. et al. Recombinant human acid α -glucosidase: Major clinical benefits in infantile-onset Pompe disease. *Neurology*. 2007 January 9; 68: 99–109.

9. Chien Y.H., Chiang S.C., Zhang X.K. et al. Early detection of Pompe disease by newborn screening is feasible: results from the Taiwan screening program. *Pediatrics*. 2008; 122 (1): 39–45.