

Yu.G. Levina^{1,2}, A.A. Alekseeva^{1,2}, E.A. Vishneva¹, K.E. Efendieva^{1,2}, A.Yu. Tomilova^{1,2}

¹ Scientific Center of Children's Health, Moscow, Russian Federation

² Sechenov First Moscow State Medical University, Russian Federation

Peculiarities of external therapy of atopic dermatitis in children: role of methylprednisolone aceponate

Author Affiliation:

Yuliya Grigor'evna Levina, MD, allergist-immunologist at the department of medical rehabilitation for children with allergic and respiratory diseases of the Scientific Center of Children's Health (Federal State Budgetary Research Institution), assistant professor at the department of allergology and clinical immunology of the faculty of pediatrics at the Sechenov First Moscow State Medical University

Address: 2/1 Lomonosovskiy Av., Moscow, 119991; **tel.:** +7 (499) 134 03 92;

e-mail: levina@nczd.ru

Article received: 16.04.2014. Accepted for publication: 17.09.2014.

The article is dedicated to the issues of external therapy of atopic dermatitis in children. Atopic dermatitis is a chronic allergic inflammatory skin disease; in most cases, it is the first manifestation of atopic march. Timely and adequate pathogenetic external therapy of this disease using topical glucocorticosteroids (TGCSs) helps to quickly and effectively terminate symptoms of the disease and allergic inflammation of the skin. Steroid phobia, which is prevalent among parents of the patients, reduced adherence to the TGCS therapy. The authors analyzed results of the original studies of effectiveness and safety of TGCSs, present general recommendations on TGCS use in children with due regard to morphofunctional peculiarities of children's skin and clinical-pharmacological description of the TGCSs featuring the most favorable therapeutic index of 0.1% methylprednisolone aceponate. Methylprednisolone aceponate available in 4 pharmaceutical forms is the optimal drug of choice for atopic dermatitis in children over 4 months of age.

Keywords: atopic dermatitis, children, treatment, topical glucocorticosteroids, effectiveness, safety, methylprednisolone aceponate.

INTRODUCTION

Atopic dermatitis (AD) is a chronic allergic inflammatory skin disease characterized by pruritus, age morphology and staging usually occurring in infants with hereditary susceptibility to atopic diseases. Out of allergic diseases, AD is considered the first and the most frequent manifestation of atopic disease observed in 80-85% of allergic infants [1-4].

Atopic dermatitis is the first manifestation of atopic march and a significant risk factor of bronchial asthma in children, as epicutaneous sensitization developing at AD is characterized not only by focal skin inflammation, but also by systemic immune response and involvement of various segments of the respiratory tract [1-4].

Long-term therapy aimed at alleviating symptoms, maintaining control over the disease and preventing further atopic march progression is required due to chronic recurrent course of atopic dermatitis with exacerbations and remissions and chronic allergic skin inflammation.

APPROACHES TO THERAPY

Topical glucocorticosteroids

External therapy aimed not only at arresting inflammation and pruritus, but also at recovering the water-lipid layer and barrier function of the skin, as well as ensuring proper daily skin care is a compulsory and important part of complex AD treatment. The primary objectives of atopic dermatitis treatment are as follows: decrease in clinical manifestations of the disease, exacerbation rate decrease, increase in life quality of patients and prevention of infectious complications [1, 3, 4].

Topical glucocorticosteroids (TGCSs) have been used for atopic dermatitis for more than 50 years and constitute the “gold standard” of treating this disease. In 1952, M.B. Suizebeger and V.H. Witten reported the first successful experience of external treatment of kin dermatosis with hydrocortisone acetate [5, 6]. Use of the first-generation topical steroids compared to the new-generation topical glucocorticosteroids was often associated with a high risk of side effects, including systemic side effects, due to the risk of the systemic blood flow penetration. TGCSs produce a complex anti-inflammatory and immunomodulatory effect. They suppress production and release of such factors as cytokines, prostaglandins and leukotrienes, which take part in allergic inflammation. Moreover, topical glucocorticosteroids produce a vasodilatory effect, alleviate intracellular edema and tissue infiltration [7].

Without any doubt, TGCSs remain the most available and effective means of treating AD in children: proper use thereof allows controlling symptoms of the disease and improve life quality of patients and their parents. However, 70-80% of parents of the children with AD, and sometimes even pediatricians, develop steroid phobia associated with fear of TGCS side effects; this is often a cause of low therapy compliance. Thus, ca. 25% of the parents note that they have not used the prescribed TGCSs due to fear of side effects.

Despite the fact that TGCSs have been used in clinical practice for more than 50 years, the data on the impact thereof on skin thickness, hypothalamic-pituitary-adrenal axis suppression and occurrence of other side effects in the event of prolonged (more than several weeks) use are insufficient [8]. It is known, however, that use of TGCSs may be accompanied by such focal side effects as skin thinning, spread of the concurrent infection, stretch marks, acne and mild skin depigmentation. Milder TGCSs are to be used for disease control in order to minimize possible side effects.

TGCS classification

Modern topical corticosteroids are classified by strength (four classes) and presence of a fluorine atom in the corticosteroid molecule (fluorinated and non-fluorinated). Taking into account the TGCS's potential to bind cytosolic receptors, block phospholipase A2 activity and reduce development of inflammation mediators, as well as the active agent's concentration, TGCSs are commonly divided into classes of activity depending on the strength thereof (in Europe – classes I-IV) combined into 4 groups (tb. 1) [3, 4]:

- very strong (class IV);
- strong (class III);
- moderately strong (class II);
- mild (class I).

Indications and contraindications

Contraindications against TGCS prescription are individual hypersensitivity to the drug's components, skin tuberculosis; viral, bacterial and fungal infections; acne, rosacea, pregnancy, lactation, skin tumors.

The general recommendations on the use of TGCSs in children are as follows:

- Start treatment with class III TGCSs in the event of severe exacerbations and localization of pathological skin foci on the body and limbs; use calcineurin or class I TGCSs to treat facial skin and other sensitive parts of skin (neck, folds).
- Class I-II TGCSs are recommended for routine localization of lesions on the body and limbs.
- Do not use class IV TGCSs in under-14 children [3, 4].

Rules and methods of use

Training programs for patients ought to be provided in order to improve therapy effectiveness and compliances. Patients and the parents thereof ought to be informed about certain rules of TGCS use: e.g., the drug is to be applied only to those parts of skin, where atopic dermatitis exacerbations were observed within 48 hours before, or to active lesion foci [8]. Determining the necessary amount of the TGCS cream or ointment applied to skin is rather challenging. Application of insufficient amount may result in lower effectiveness of the drug; intensive use – in undesirable local side effects. In order to determine an optimal amount of drug applied to the child's skin with signs of allergic inflammation, finger tip units (FTUs) are employed (pic. 1). Cream or ointment is pressed out of a tube on the index finger's tip. The necessary amount of FTUs depends on the child's age and the body zone, where atopic dermatitis manifestations are localized [9] (tb. 2).

TGCS application frequency depends on the steroid's pharmacokinetic peculiarities: thus, e.g., methylprednisolone aceponate is to be applied OD, fluticasone – OD-BID, betamethasone, prednisolone and hydrocortisone 17-butyrate – BID-TID. Prescription of short courses (3 days) of strong TGCSs to children is as effective as long-term application (7 days) of mild TGCSs^{A1}. Dilution of official topical TGCSs with indifferent ointments for external AD therapy is not recommended, as the resulting formula's composition does not guarantee absence of side effects (proved by randomized controlled studies^C); use thereof is characterized by significant decrease in therapeutic effectiveness of topical TGCSs. In the event of significant decrease in intensity of the disease's clinical manifestations, TGCSs may be applied intermittently (usually – TIW) together with nutrients in order to maintain remission of the disease, but only if long-term TGCS therapy is justified by undulating nature of the disease^A. It ought to be mentioned that long-term intermittent TGCS therapy is undesirable due to the risk of increase in the frequency of adverse drug reactions. Use of TGCSs (in the absence of infectious complications) is as effective as topical combined GCS drugs^A [3, 4].

The order of application of TGCSs and emollients has remained controversial until now. Clinical recommendations on emollient therapy published by the International Skin Care Nursing Group (ISNG) indicate that topical steroids ought to be applied after emollients have soaked in (the skin must be moisturized). According to the clinical study, upon which these recommendations are based, a well moisturized skin requires a smaller amount of a corticosteroid (corticosteroid-saving effect), whereas application of an anti-inflammatory hormone immediately prior to an emollient may result in the drug's dilution and steroid spread to the zones, which do not require treatment [10].

Effectiveness and safety of TGCSs

The benefit-risk ratio (therapeutic index) of TGCSs for use in children is preferable in this population. Higher ratio between skin area and body weight in infants leads to rapid absorption of any drugs used for external therapy; drug metabolism is slower in children than in adults; systemic effects of corticosteroids may be more pronounced (particularly, decrease in blood serum cortisol due to hypothalamic-pituitary-adrenal axis suppression). In children, skin continuously develops in the anatomico-physiological regard. Rapid physiological change of epidermal layers and dyshesion of keratinizing cells result from intensive mitosis not only in the basal layer, but also in the spinous and granular layers [7, 11]. The younger the child, the thinner

¹ A-C – levels of strength used in evidence-based medicine.

the skin and the more sensitive the skin to external effects. This is aggravated by imperfection and lability of immune processes in the child's body, as well as a large amount of mast cells in derma. The latter play an important role in immediate allergic reactions; when breaking down, they release biologically active substances (histamine, heparin, hyaluronidases, proteases etc.) contributing to increased permeability of vascular walls and tissues.

Unlike in adults, derma in children is characterized by predominance of connective tissue cells (histiocytes, fibroblasts, mastocytes, melanoblasts), whereas collagen and elastic fibers are underdeveloped. In the setting of high skin vascularization, vascular vessels have only layer of endothelial cells. This predetermines intensity of skin penetration intensity by the externally applied drugs [11].

Methylprednisolone aceponate

Class III TGCS structure modification resulted in higher activity and the same risk of side effects; these drugs have a high therapeutic index. One of the class III TGCSs is 0.1% methylprednisolone aceponate (Advantan, Bayer Schering Pharma AG, Germany), which demonstrates high effectiveness and tolerance in infants and children. According to the German Dermatological Society, out of the existing TGCSs methylprednisolone aceponate has the highest therapeutic index, i.e. a high ratio of risk of side effects and therapeutic effectiveness (tb. 3) [12, 13].

Methylprednisolone aceponate is a non-halogenated 6 α -methylprednisolone diester. Placement of the methyl group to position C6 leads to high activity of methylprednisolone aceponate. Absence of chlorine and fluorine in positions C6, C9 or C12 typical of most strong TGCSs allows minimizing local and systemic side effects. Double esterification (in positions C17 and C21) ensures the molecule's optimal lipophilicity, rapid penetration of the epidermis and high concentration in derma (pic. 2) [12, 14-17].

Atrophogenic potential (skin thinning and development of telangiectasia) of the drug under analysis is lower or comparable to such a potential of other class III drugs, such as 0.1% betamethasone valerate and 0.1% mometasone furoate. However, decrease in blood plasma cortisol was observed in some of the healthy volunteers applying 30 g of 0.1% methylprednisolone aceponate ointment to the skin covered with occlusive dressing for 5 days. Pituitary-adrenal function in patients with various dermatoses treated with methylprednisolone aceponate remained undepressed even after a 4-months-long therapy [17]. It is extremely important for pediatric practice that methylprednisolone aceponate is not capable of affecting circadian rhythm of the endogenous glucocorticoid's level [12]. Thus, clinical studies of 7-days-long eczema treatment in children (daily application of 0.1% ointment to 5-20% of body surface) did not reveal inhibition of the pituitary-adrenal function, although pronounced therapeutic effects were observed [18].

As methylprednisolone aceponate undergoes transformation, an active metabolite – 6 α -methylprednisolone-17-propionate – forms in skin; it binds with glucocorticoid receptors within the cell; this stimulates a range of biological processes, one of which is formation of macrocortin. Macrocortin inhibits release of arachidonic acid and production of inflammatory markers, such as prostaglandins and leukotrienes. Penetrating blood flow in minimal concentrations (0.27-2.5%), methylprednisolone aceponate rapidly and completely binds with glucuronic acid and is inactivated in liver [14].

It is especially important for pediatric practice that methylprednisolone aceponate is permitted to use in children as young as 4 months of age. Deposition in epidermis and affinity for GCS-receptors of skin cells allow using the drug OD by thinly applying it to the inflamed site. Duration of use ought not to exceed 4 weeks. Advantan is produced in 4 forms: cream, ointment, greasy ointment and emulsion; this satisfied needs of small patients and the parents thereof, along with high therapeutic index. The preferable pharmaceutical form depends on the stage and manifestations of atopic dermatitis (pic. 3) [14].

Emulsions are easy to apply, especially to damaged skin; the drying and cooling effect thereof reinforces anti-inflammatory and anti-allergic effect of the primary active substance – corticosteroid. 0.1% methylprednisolone aceponate emulsion features these properties, as well as disinfecting (polyoxyethylene stearyl alcohols) and dermatoprotective (glycerol) effects [19]. Thanks to softisan (which helps to recover skin hydrolipidic mantle), 0.1% methylprednisolone aceponate may be used until complete recovery in the event of atopic dermatitis exacerbation accompanied by skin integrity damage [20].

In the event of acute inflammation, it is reasonable to use creamed topical corticosteroids. 0.1% methylprednisolone aceponate **cream** produces a pronounced anti-inflammatory effect potentiated thanks to the base composition peculiarities (the same applies to the emulsion): cetostearyl alcohol promotes cell membrane fat synthesis, while decyl oleate improves the drug's texture and plasticity, which softens skin surface.

In the event of a chronic inflammation requiring additional softening and moistening of dry skin, topical corticosteroid ointments are preferable. 0.1% methylprednisolone ointment ensures immediate effect and features emollient, protective and wound-healing action thanks to liquid paraffin and bleached beeswax [21-23]. Long-term chronic inflammation characterized by pronounced hyperkeratosis, infiltration and lichenification requires using an occlusive topical corticosteroid. 0.1% methylprednisolone aceponate promotes rapid size reduction of the inflamed site; anhydrous base of **greasy ointment** softens skin and recovers the natural moisturizing level by means of hydrogenated castor oil; microcrystalline wax helps to cover skin with hard protective film [24].

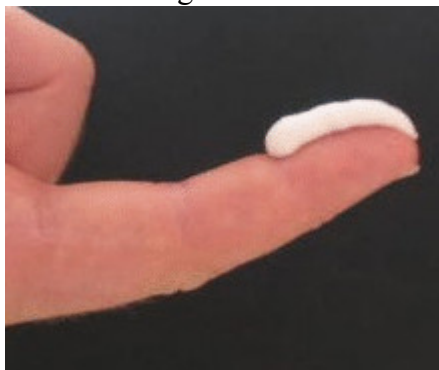Effectiveness of topical glucocorticosteroid drugs depends on the rate of the penetration thereof into epidermis and derma. Skin moisturizing, drug concentration increase and the drug's lipophilicity help to increase skin permeability for TGCSs. The higher the lipophilicity, the higher the concentration in skin cells and the lower – in blood. The optimal lipophilicity (octanol/water distribution ratio) of steroids ensuring rapid biomembrane penetration thereof varies from 2,000 to 3,000 (e.g., this ratio for methylprednisolone aceponate is ca. 2,500, for hydrocortisone butyrate [Locoid] – 160) [25, 26]. The lower the water concentration in the pharmaceutical form, the higher the epidermis penetration rate (tb. 4).

Numerous international [17] and Russian [11, 27] clinical studies indicate high effectiveness and safety of this drug in children. Comparative studies have demonstrated that topical 0.1% methylprednisolone aceponate cream, ointment or greasy ointment are as effective as 0.1% betamethasone valerate and 0.1% hydrocortisone valerate in the same pharmaceutical forms. Ca. 90% of the children treated with methylprednisolone aceponate achieved remission or significant improvement in 1-3 weeks of therapy; complete remission was observed in 45-65% of the patients [17].

A randomized double-blind study performed by T. Bieber et al. was dedicated to comparative assessment of effectiveness of methylprednisolone aceponate and tacrolimus in children with severe and extremely severe atopic dermatitis. The study confirmed that methylprednisolone aceponate is the first-line drug for atopic dermatitis in children. Patients (n = 265) were randomized to groups of methylprednisolone aceponate (n = 129) and tacrolimus (n = 136); 257 patients completed the study. The drugs were used for 2-3 weeks, and for 7 days after skin purging. Emollients were permitted to use when necessary. 0.1% methylprednisolone aceponate ointment ensured rapid and significant clinical improvement when applied to the damaged body surface OD. 0.03% tacrolimus ointment applied BID demonstrated the same effectiveness score on the Investigators Global Assessment (IGA) index change scale. Complete or almost complete skin purging off atopic dermatitis manifestations was observed in 2/3 of the patients. Despite equivalent effectiveness of the drugs, more children with complete clean skin were observed in the methylprednisolone aceponate group by the end of the study (37.2 and 29.4%, respectively). Moreover, methylprednisolone aceponate outperformed tacrolimus in terms of impact on the Eczema Area and Severity Index (EASI), pruritus and sleep. Adverse drug-induced effects were

observed only in the tacrolimus group: 4 children therefrom were excluded from the study due to adverse effects. Medical costs were far lower in the methylprednisolone aceponate group [28].

Pic. 1. Dosage unit of local corticosteroids — FTU

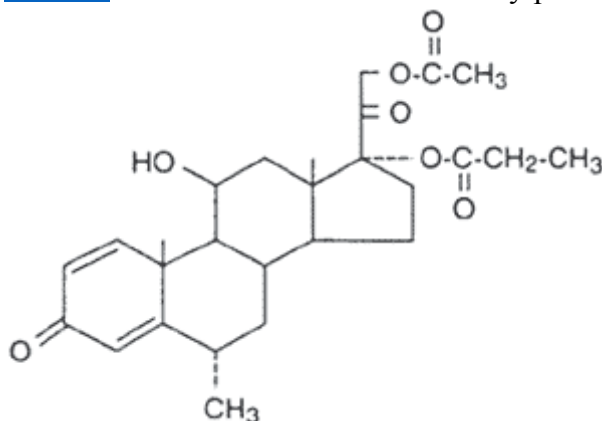


Note. FTU (fingertip unit) - a unit equal to the fingertips.

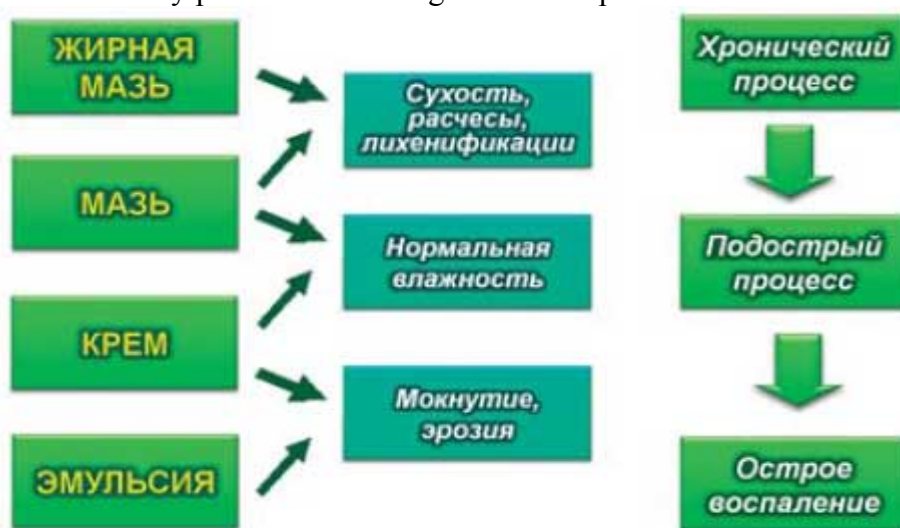Pic.

2.

<http://www.google.ru/url?source=transpromo&rs=rssf&q=//translate.google.com/community?source=all> The chemical structure of methylprednisolone atseponat



Pic. 3. Methylprednisolone dosage forms atseponat



Жирная мазь - Oily Ointment, Мазь - Ointment, Крем - Cream, Эмульсия - Emulsion

Сухость, расчесы, лихенификации - Dryness, scratching, lichenifications, Нормальная влажность - normal humidity, Мокнутие, эрозия - Moisture, erosion

Хронический процесс - Chronic process, Подострый процесс - Subacute process, Острое воспаление - acute inflammation

Proactive AD therapy

External therapy with anti-inflammatory drugs was for a long time used conventionally only in the period of disease exacerbation, in the presence of visible inflammatory skin alterations. The new treatment strategy signifies a so called proactive approach to long-term therapy of atopic dermatitis, especially of severe atopic dermatitis with frequent exacerbations.

Proactive approach to treatment implies use of intensive TGCS therapy until skin purging off atopic dermatitis manifestations and further intermittent application of a low dose of an anti-inflammatory drug to the site where atopic dermatitis elements had been observed in order to prevent the disease exacerbation. Immunobiological justification of this proactive approach is based on the fact that despite the esthetic appearance, skin of a patient with atopic dermatitis actually features a barrier malfunction [29], subclinical inflammation [30] and high expression of a high-affinity IgE-receptor on Langerhans cells [31].

If atopic dermatitis exacerbations are observed more than 2-3 times per month, intermittent TGCS therapy BIW may be considered to prevent frequent disease exacerbations until control over the disease has been achieved. This strategy ought to be revised after 3-6 months [8].

Placebo-controlled studies of proactive therapy effectiveness for preventing atopic dermatitis exacerbations were performed using topical tacrolimus, fluticasone propionate and methylprednisolone aceponate. Thus, a 16-weeks-long study demonstrated superiority of methylprednisolone aceponate over placebo and absence of disease exacerbation in 87.1% of the patients (placebo – 65.8%). Methylprednisolone aceponate was more effective than emollients regarding the frequency of relapses, pruritus intensity and the Dermatology Life Quality Index (DLQI) in children [32].

CONCLUSION

Alleviation of AD symptoms with class III topical corticosteroids, e.g., methylprednisolone aceponate, is an optimal therapeutic choice for children and infants due to a high therapeutic index and diversity of the drug's pharmaceutical forms. Regular educational programs for patients and parents, oral and written explanation of the primary rules of using external therapy means for atopic dermatitis are required to improve therapy effectiveness, overcome steroid phobia and increase therapy compliance.

CONFLICT OF INTEREST

The authors have indicated they have no financial relationships relevant to this article to disclose.

REFERENCES

1. Namazova-Baranova L.S., Kulichenko T.V., Borovik T.E., Makarova S.G., Novik G.A., Petrovskii F.I., Vishneva E.A., Alekseeva A.A. *Atopicheskiei dermatit: rukovodstvo dlya vrachei. Ser. «Bolezni detskogo vozrasta ot A do Ya»* [Atopic Dermatitis: a Guide for Physicians. Series "Diseases of Childhood from A to Z"]. Moscow, Pediatr"", 2014. 71 p.
2. Spergel J.M., Paller A.S. Atopic dermatitis and the atopic march. *J Allergy Clin Immunol.* 2003; 112 (Suppl. 6): 118–127.
3. *Allergologiya i immunologiya. Pod obshchei red. A.A. Baranova i R.M. Khaitova* [Allergy and Immunology. Edited by A.A. Baranov, R.M. Khaitov]. Moscow, Soyuz pediatrov Rossii, 2011. 248 p.

4. Namazova-Baranova L.S. *Allergiya u detei: ot teorii k praktike* [Allergies in Children: from Theory to Practice]. Moscow, 2010. 668 p
5. Sulzberger M.B., Witten V.H. The effect of topically applied compound F in selected dermatoses. *J Invest Dermatol.* 1952; 19: 101–102.
6. Shakhtmeister I.Ya. Problems in the rational use of medicines outside of glucocorticoid nature in pediatric practice. *Detskii doktor = Pediatrician.* 1998; 1.
7. Alekseeva A.A., Levina Yu.G., Vishneva E.A., Arshba S.K. Application of topical corticosteroids in the standard regimen of atopic dermatitis in children. *Voprosy sovremennoi pediatrii = Current Pediatrics.* 2009; 8 (6): 146–150.
8. Atopic Eczema in Children. Management of Atopic Eczema in Children from Birth up to the Age of 12 years. NICE Clinical Guidelines, № 57. *London: National Collaborating Centre for Women's and Children's Health.* 2007. Available at: <http://www.nice.org.uk/guidance/CG57>
9. Long C.C., Mills C., Finlay A.Y. A practical guide to topical therapy in children. *Br J Dermatol.* 1998; 138: 293–296.
10. Ersser S., Maguire S., Nicol N. et al. A best practice statement for emollient therapy. *Dermatological Nursing.* 2007. P. 1–19.
11. Grebenyuk V.N., Balabolkin I.I. *Pediatriya = Pediatrics.* 1998; 5: 88–94.
12. Zaumseil R.-P., Fuhrmann H., Kecskes A., Taeuber U., Toepert M. Methylprednisolone aceponate (Advantan) — an effective topical corticoid therapy with few side effects. *Jahrb Dermatol.* 1992; 3: 247–263.
13. Luger T.A., Loske K.D., Elsner P., Kapp A., Kescher M., Korting H.C. et al. Topical dermatological therapy with glucocorticoids — therapeutic index. *JDDG.* 2004; 2: 629–634.
14. *Topicheskie steroidy. Advantan. Informatsiya o preparate* [Topical Steroids. Advantan. Information about the Drug]. Moscow, 2001.
15. Meffert H., Schuppler J. Methylprednisolone aceponate lotion for treatment of acute eczema. *Zeitschrift fur Hautkrankheiten.* 1999; 74: 88–94.
16. Volkova E.N., Lange D.A., Rodina Yu.A., Tarasova M.V. Methylprednisolone atseponat in the complex therapy of chronic dermatoses: analysis of tactical errors of application. *Klinicheskaya dermatologiya i venerologiya = Clinical Dermatology and Venereology.* 2010; 5: 84–88.

17. Haria M., Balfour J.A. Methylprednisolone aceponate. A review of its pharmacological properties and therapeutic potential in the topical treatment of eczema. *Clin Immunother.* 1995; 3: 241–253.
18. Giannotti B., Haneke E. Eczema. *England.* 1995. 74 p.
19. Free C.L., Simon A., Ohlmeyer H. et al. Prevention of stratum corneum lipid phase transitions in vitro by glycerol- an alternative mechanism for skin moisturisation. *J Soc Cosmet Chem.* 1990; 41: 51–65.
20. Ioffe D.V. Zhiry. V kn.: *Khimicheskaya entsiklopediya* [Fats. In: Chemical Encyclopedia]. Moscow, Sovetskaya entsiklopediya, 1990. P. 155–157.
21. Nguyen S.H., Dang T.P., Maibach H.I. Comedogenicity in rabbit: some cosmetic ingredients/vehicles. *Cutan Ocul Toxicol.* 2007; 26 (4): 287–292.
22. Mao-Qiang M., Brown B.E., Wu-Pong S. Exogenous Nonphysiologic vs Physiologic Lipids. *Arch Dermatol.* 1995; 131 (7): 809–816.
23. Fulton J.R. Comedogenicity of commonly used ingredients. *J Soc Cosmet Chem.* 1989; 4: 321–333.
24. Korsunskaya I.M., Dvoryankova E.V. The role of topical glucocorticosteroid form in achieving optimal treatment effect steroidchuvstvitelnyh dermatoses. *Klinicheskaya dermatologiya i venerologiya = Clinical Dermatology and Venereology.* 2012; 4: 3.
25. Petrova G.A. *Naruzhnaya kortikosteroidnaya terapiya dermatozov* [Outdoor Corticosteroid Therapy of Dermatoses]. Nizhny Novgorod, NGMA, 2000.
26. Kubanova A.A., Samsonov V.A., Averbakh E.V. et al. Elokim in treating psoriasis and atopic dermatitis. *Vestnik dermatologii i venerologii = Bulletin of Dermatology and Venereology.* 1996; 5: 10–12.
27. Korotkii N.G., Taganov A.V., Shimanovskii N.L. *Opyt primeneniya Advantana (metilprednizolona atseponata) v detskoj dermatologicheskoi praktike pri lechenii atopicheskogo dermatita* [Experience of Application of Advantan (methylprednisolone atseponat) in Pediatric Dermatology Practice in the Treatment of Atopic Dermatitis]. Moscow, Zhurnal SMU, 2005. P. 3.
28. Bieber T.I., Vick K., Fölster-Holst R., Belloni-Fortina A., Städtler G., Worm M., Arcangeli F. Efficacy and safety of methylprednisolone aceponate ointment 0,1%

compared to tacrolimus 0,03% in children and adolescents with an acute flare of severe atopic dermatitis. *Allergy*. 2007 Feb; 62 (2): 184–9.

29. Proksch E., Foelster-Holst R., Jensen J.M. Skin barrier function, epidermal proliferation and differentiation in eczema. *J Dermatol Sci*. 2006; 43: 159–169.
30. Mihm M.C., Soter N.A., Dvorak H.F. The structure of normal skin and the morphology of atopic eczema. *J Invest Dermatol*. 1976; 67: 305–312.
31. Wollenberg A., Wen S., Bieber T. Phenotyping of epidermal dendritic cells: clinical applications of a flow cytometric micromethod. *Cytometry*. 1999; 37: 147–155.
32. Peserico A., Städtler G., Sebastian M., Suarez Fernandez R., Vick K., Bieber T. Reduction of relapses of atopic dermatitis with methylprednisolone aceponate cream twice weekly in addition to maintenance treatment with emollient: a multicentre, randomized, double-blind, controlled study. *Br J Dermatol*. 2008; 158: 801–807.