

N.D. Vashakmadze, G.V. Revunenkov, E.G. Chernavina, O.V. Kustova, M.V. Tarayan, I.V. Davydova, A.K. Gevorkyan

Scientific Center of Children's Health, Moscow, Russian Federation

Child with Combined Cardiorespiratory Pathology. Clinical Case

Author affiliation:

Vashakmadze Nato Dzhumberovna, MD, head of the medical rehabilitation department for children with cardiovascular system diseases of the research institute of preventive pediatrics and medical rehabilitation of SCCH, RAMS

Address: 2, Lomonosovskii ave., Moscow, 119991, **tel.:** +7 (499) 134-08-15, **e-mail:** nato-nato@yandex.ru

Article received: 11.12.2012, accepted for publication: 24.03.2013

The course of a secondary pulmonary hypertension in a child with congenital heart disease and bronchopulmonary dysplasia in anamnesis is retraced in the article using a concrete clinical case. An assessment of echocardiographic and radiologic disease signs at a prolonged follow-up observation of a child with combined cardiorespiratory pathology was conducted. The main therapeutic approaches to this category of patients were covered.

Keywords: *secondary pulmonary hypertension, congenital heart disease, artificial pulmonary ventilation, bronchopulmonary dysplasia, computed tomography of thoracic cavity organs.*

Introduction

Bronchopulmonary dysplasia (BPD) remains one of the most frequent infancy pathologies. There is a high risk of unfavorable outcome and formation of a chronic respiratory pathology resulting in a child's incapacitation in case of severe complicated BPD course with frequent exacerbations of bronchopulmonary process [1]. Pulmonary hypertension (PH) is a severe complication of bronchopulmonary dysplasia. The frequency of pulmonary hypertension forming at BPD has not yet been reliably determined and depends on population and age of patients, disease course variant and the used method of diagnostics. Frequency of PH in children of 0-1 years of life is 21%, of pulmonary heart disease – 6% [2]. Thus, pulmonary heart disease in children with BPD is observed far rarer than at the initial disease description [3]; this may be associated with BPD pathomorphism.

Intense PH is the only independent predictor of unfavorable prognosis and death of children with BPD [4]. PH also sometimes causes a relatively late death (after 6 months) in children with BPD, even if bronchopulmonary process takes favorable course.

Pathogenesis

Pulmonary hypertension pathogenesis is the progressive luminal narrowing of minute and intermediate branches of the pulmonary artery caused by the development of hypertrophy of the vascular wall's muscular layer with a possible complete obliteration of minute vessels' lumen. The mentioned pulmonary artery's alterations cause a gradual pressure increase in the lesser circulation. Pulmonary artery's average pressure increase at rest over 25mm Hg is a criterion of pulmonary hypertension at chronic pulmonary diseases; normally, this parameter is 9-16mm Hg. Continuous pressure increase in the pulmonary artery result in the right ventricle wall's hypertrophy. With the lapse of time, right ventricle ceases to cope with the progressing pulmonary hypertension; this leads to reduction in its contractile (pumping) ability and development of right ventricular insufficiency.

Classification

There is no universally accepted classification of secondary PH associated with hypoxemia. Different classifications take into account severity and ethiopathogenetic signs. Pulmonary hypertension associated with the respiratory system's pathology and hypoxemia belongs to the modern lesser circulation hypertension classification developed by the group of experts from the European Society of Cardiology (ESC) and the European Respiratory Society (ERS) [5]. The new Panamanian classification of pulmonary hypertension (2011) developed by the pediatric workgroup from the Pulmonary Vascular Research Institute (PVRI) lists a range of categories of pulmonary hypertension caused by pulmonary diseases and hypoxemia (tb. 1).

This classification emphasizes yet another fundamental difference of PH in children – a possibility for the disease to form during the ontogenesis of lungs and their vessels, especially in perinatal period. Any impact on pulmonary vessels in pre- and postnatal periods may lead to deadaptation, development defects and growth inhibition. Altered ontogenesis manifests itself with pulmonary hypoplasia, BPD and alveolar-capillary dysplasia [6, 7]. Moreover, this classification emphasizes a multifactor PH genesis in pediatric patients even at specific nosologic forms. E.g., PH may develop on basis of pulmonary hypoplasia and/or pulmonary vascular development delay and genetic syndromes at BPD or interstitial pulmonary diseases. Patients with BPD may have PH associated with intermittent chronic hypoxia, hypercapnia due to the damaged pulmonary and airway tissue, diastolic dysfunction, pulmonary vein stenosis, congenital heart diseases and pulmonary-to-systemic shunt [4, 8, 9].

Treatment

PH treatment includes: oxygen, diuretics, digoxin (in case circulatory deficiency progresses), anticoagulants, vasodilators (in case vasoreactivity test is positive), endothelin antagonists, prostaglandins and their analogs,

phosphodiesterase inhibitors and surgical treatment modes (interatrial shunting, lung transplantation, cardiopulmonary transplantation). Tracleer (bosentan) is among the most recommended antagonists of endothelial receptors A and B. According to the latest research, bosentan is recommended to treat the II functional class PH in the USA and Europe in children over 2 years of age; this makes it the only permitted pediatric drug. In the RF, bosentan is used to treat pulmonary arterial hypertension in children over 3 years of age. It should be noted that bosentan is the only registered drug for specific therapy of pulmonary arterial hypertension in Russia. Bosentan is prescribed to children given their body weight (100mg/kg per day).

Definition

Bronchopulmonary dysplasia is a polyetiologic chronic disease of morphologically immature lungs developing in newborns, especially in small premature infants, due to the intensive therapy of respiratory distress-syndrome and/or pneumonia. It progresses with the development of emphysema, fibrosis and/or alveolar replication abnormality; the most affected parts are bronchioles and pulmonary parenchyma; it manifests itself with oxygen dependence at the age of 28 days and older, broncho-obstructive syndrome and respiratory failure signs and is characterized by specific radiographic alterations in the first months of life and regression of clinical manifestations as children grow [10].

Bronchopulmonary dysplasia diagnostics criteria

- artificial pulmonary ventilation (APV) in the 1st week of life and/or respiratory therapy with nose continuous positive airway pressure (NCPAP);
- more than 21% oxygen therapy at the age of 28 days and older (oxygen dependence);
- respiratory failure, broncho-obstructive syndrome at the age of 28 days and older, oxygen dependence developing due to oxygen therapy (APV, NCPAP);
- interstitial edema intermittent with increased pulmonary tissue transparency segments, fibrosis, ribbon-like indurations seen on the chest roentgenogram.

Diagnosis “Bronchopulmonary dysplasia” is justified as independent only in children under 3 years of age. At an older age BPD is mentioned only as a past disease.

The main method of diagnosing the disease is radiology (radiography and chest computed tomography). Rating scale was proposed and patented in 2010 in order to determine the intensity of radiographic alterations objectively [11, 12]; each diagnostic sign is given from 0 to 3 points, 0 being “no sign”. The disease course is determined according to the sum of points: 1-5 – mild course, 6-10 – moderate course, 11-15 – severe course of bronchopulmonary dysplasia (tb. 2).

Treatment

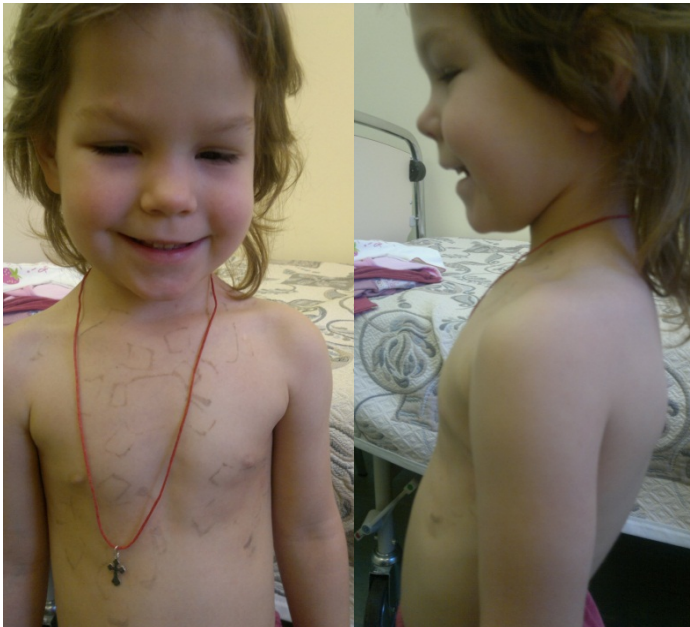Long-term (up to 6-12 months) baseline corticosteroid therapy is indicated for children with BPD; at present, the preference is given to inhalation corticosteroids – budesonide (Pulmicort) of 500-100 mcg/day using a compression nebulizer. Budesonide withdrawal criterion is the lack of broncho-obstructive syndrome at another acute respiratory viral infection (ARVI). It is indicated to use diuretics (2 mg/kg of furosemide), broncholytics (Berodual (1 drop per 1 year of life) TID-QID using a nebulizer) and cardiotropic drugs in the acute period. Antibiotic therapy is prescribed according to indications. In case additional oxygenation is needed, desirable proportion of SaO₂ is ≥92-95%; in children developing pulmonary heart diseases – up to 96% [12, 13].

Medical rehabilitation department for children cardiovascular diseases admitted girl B. of 4 years 9 months of age (22.01.2008) complaining of dyspnea at rest, rapid fatigability and weakness. History taking revealed that the girl was the first-pregnancy child; the mother contracted a respiratory infection during the 33rd gestation week; unassisted delivery in the 39th gestation week; meconium waters at delivery. The girl was born full-term; birth weight – 3,140g, length – 55cm. Condition at birth was assessed as critical due to meconium aspiration, respiratory failure and neurological symptoms; resuscitation was conducted. Until 3.5 months of age she remained at the CCH resuscitation department in Lyubertsy with the diagnosis “Agnogenic congenital pneumonia”. APV was being conducted for 51 days. Since 3.5 months of age the child has been observed at the SCCH with the diagnosis “BPD of the full-term, severe course, exacerbation period. Congenital heart disease. Patent ductus arteriosus. Atrial septal defect. Pulmonary hypertension. Cardiopulmonary decompensation 1-2 A. Congenital malformation of the visual analyzer – aniridia”. Long-term oxygen dependence had been noted; the girl required constant O₂ supply using an oxygen concentrator with nasal oxygen tubes from 0 to 3 years of age, after 3 years of age – during ARVI. She continuously received Pulmicort inhalation therapy of 250mcg BID before 2 years of age due to the condition severity, after 2 years of age – during ARVI. She has been prescribed Capoten, Digoxin, Triampur and Furosemide therapy since 3.5 months of age. Domiciliary, drugs were given irregularly and were voluntarily withdrawn by the mother in June 2011 due to underestimation of the child’s condition severity. The child was admitted to a new examination 6 months after the supporting therapy had been withdrawn, at the age of 4 years 9 months (pic. 1).

Condition at admission – severe. Forced attitude – shoulders cramped forward. Body weight – 13.5kg, height – 102cm, physical development – below the average. Acrocyanosis. Cushingoid phenotype. Deformation of the left chest, “cardiac hump” formation. Auscultation – diminished irregular pulmonary breathing, no crepitation. Dyspnea at rest (up to 40 per minute), accessory muscles. Auscultation – rasping systolic murmur throughout chest. Diastolic shock – on the base to the left. Relative heart dullness percussion borders: left - +1.5cm off the

midclavicular line, right - +1cm off the sternal border, upper - 3rd intercostal space. Liver and spleen - not enlarged on palpation. Laboratory examination of the general blood analysis of 26.10.21: RBC - 5.68mn (3.9-5.3), Hb - 162g/l (115-140), HCT - 50% (34-40), PLT - 295,000, WBC - 7,340, segmentonuclear neutrophils - 52%, lymphocytes - 33% (35-55), monocytes - 6.7%, ESR - 4mm/h, SaO₂ - 88-87% without additional oxygen input at rest.

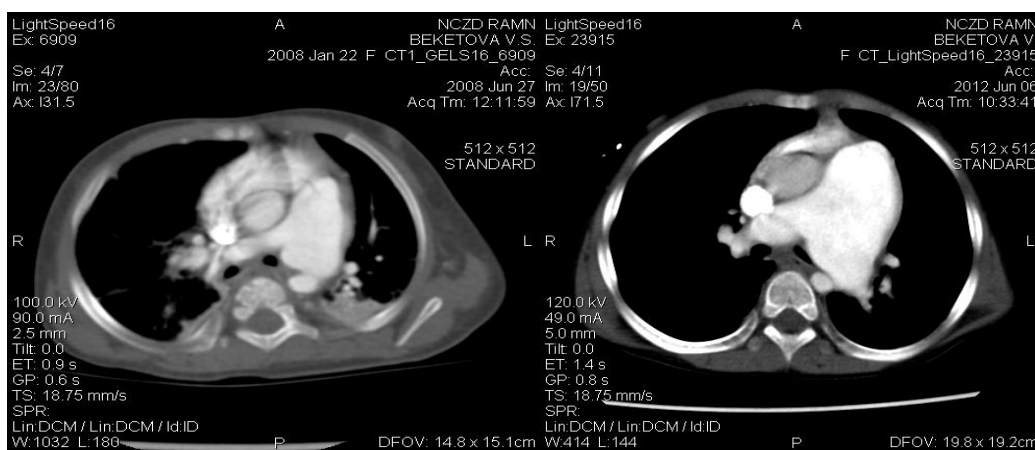
Pic. 1. Appearance of the patient V., 4 years 9 months



Electrocardiogram - heart electrical axis's disturbance to the right. Pacemaker's migration from sinus to the right atrial myocardium. High-grade arrhythmia. Signs of the right ventricular myocardial hypertrophy. Non-specific intraventricular heart block. According to echocardiogram: patent foramen ovale, muscular ventricular septal defect. Moderate right ventricle's dilation (23mm), total pulmonary valvular incompetence, high-grade trunk (up to 35mm) and branch dilation (right - 17mm, left - 17.5mm). Pulmonary venous dilation. I grade mitral regurgitation. Ascending aortic dilatation (14mm). Insignificant aortic valvular stenosis. Satisfactory left ventricle's global and local systolic functions. Sufficient cardiac pumping ability. II grade pulmonary hypertension (lesser circulation's pressure was impossible to assess in absolute values, pulmonary arterial pressure - equal or higher than the systemic pressure, child's arterial pressure - 95/55mmHg), no clear data for the pathological reflux on a projection of the pulmonary arterial trunk's bifurcation. According to echocardiogram: right ventricular anterior wall's excursion normalization in dynamics in the setting of Capoten and Furosemide therapy (6 to 4.5mm), right ventricle's size loss (23 to 19mm). Pulmonary arterial pressure measurement using invasive, anesthetic techniques was not conducted due to the child's severe condition and apnea episodes at anesthesia listed in anamnesis.

In order to confirm patent ductus arteriosus (PDA) and diagnose the pulmonary affection character the patient repeatedly endured computed tomography of thoracic cavity organs with IV bolus contrast; results were appraised in dynamics from the age of 4 months. Computed tomography confirmed vascular communication of pulmonary artery and aorta; its pulmonary outflow is located immediately to the left of the pulmonary arterial trunk's bifurcation, aortic outflow – by the anterolateral aortic wall, distally off the beginning of the left subclavian artery (topographic-anatomic location conformed to PDA). PDA caliber increase was noted in the setting of irregular intake of drugs and complete therapy withdrawal by the mother at the age of 3.5 years. PDA increased from 9mm at 4 months of age to 19mm at present (pic. 2). Progressive enlargement of the pulmonary arterial trunk: from 17mm at 4 months of age to 35mm at present.

Pic. 2. Patent ductus arteriosus



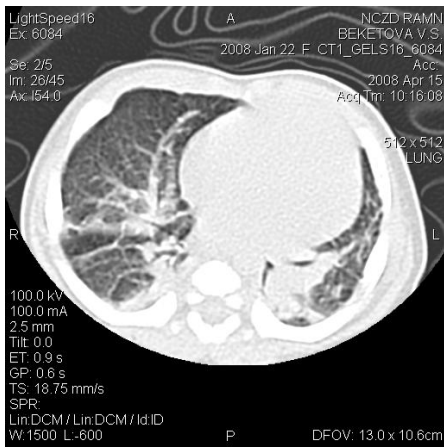
At the age of 4 months

At the age of 4 years 5 months

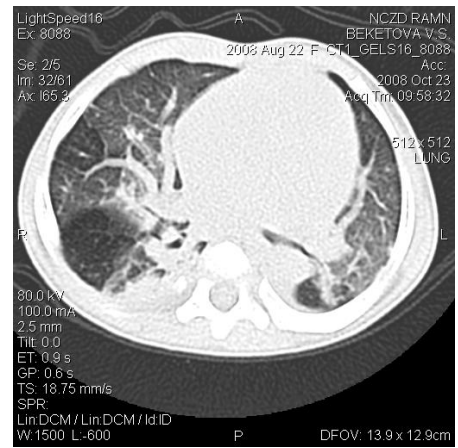
According to the computed tomography at the age of 4 months, pulmonary imaging featured severe bilateral pulmonary affection (corresponding to bronchopulmonary dysplasia with the maximal sum of 15 points on a rating scale; see tb. 2, pic. 3). Healthy pulmonary tissue volume increased from the age of 9 months to 1 year 10 months; pulmonary tissue pneumatization improvement. Pneumatization irregularity with increased airiness segments and multiple transpulmonary bands deforming costal pleura leaves remained (pic. 4-5). Volume of the left lung's inferior lobe slightly reduced. Local pulmonary fibrosis S10 formed in the left lung's inferior lobe (pic. 6).

Pic. 3. Bronchopulmonary dysplasia,

Pic. 4. Bronchopulmonary dysplasia, severe course, 15 points



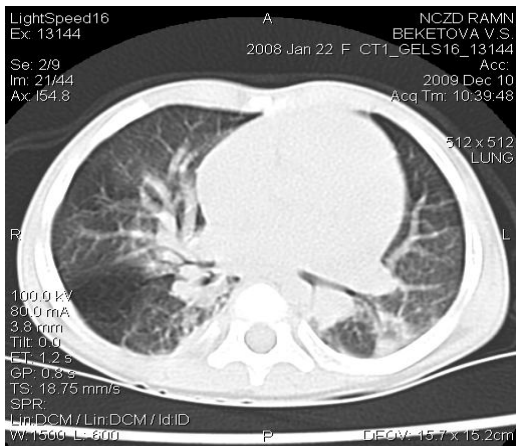
4 months



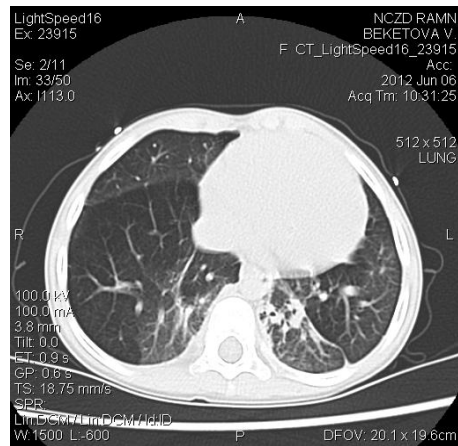
9 months

Pic. 5. Bronchopulmonary dysplasia, 15 points

Pic. 6. Outcome of bronchopulmonary dysplasia. Formation of local pulmonary fibrosis



1 year 10 months



4 years 5 months

On the basis of anamnestic data and conducted laboratory and instrumental studies, the clinical diagnosis established: “Congenital heart disease. Patent ductus arteriosus. Atrial septal defect. Ventricular septal defect, hemodynamically insignificant muscular defect. Total pulmonary valvular incompetence. Mitral incompetence. Insignificant aortic valvular stenosis. High pulmonary hypertension. Bronchopulmonary dysplasia – in anamnesis. Local pulmonary fibrosis S10 in the left lung’s inferior lobe. Obliterating bronchiolitis. II grade cardiopulmonary decompensation. Congenital malformation of the visual analyzer – aniridia”.

Capoten therapy (1 mg/kg of body weight per day (15mg per day) TID) restored. At present, the child takes Enap (0.3mg/kg per day). Furosemide therapy restored (1/8 of a tablet per day, in the morning). No common opinion on a possible introduction of bosentan into the therapy. Oxygen and budesonide inhalation therapy are recommended during ARVI.

At present, pulmonary hypertension in a child is secondary and takes its course in the setting of a multisystem affection of cardiorespiratory system.

Oxygen and budesonide inhalation therapy furthered regression of initial pulmonary alterations and resulted in obliterating bronchiolitis and local pulmonary fibrosis. Cardiac therapy withdrawal by the mother furthered the child's condition decompensation. It remains an open question if the PDA should be closed in this child, as on this stage it appears to be the only compensatory vascular communication preventing the child's condition breakdown.

REFERENCES

1. Baranov A.A., Davydova I.V., Turti T.V., Namazova-Baranova L.S., Altunin V.V., Zimina E.P., Pavlyukova E.V. *Pediatrichestkaya farmakologiya – Pediatric pharmacology*. 2012; 9 (6): 48–53.
2. Degtyareva E.A., Ovsyannikov D.Yu., Zaitseva N.O. et al. *Legochnaya gipertenziya i «legochnoe serdtse» u detei s bronkhologochnoi displaziei: chastota, faktory riska, terapiya* [Pulmonary Hypertension and "Pulmonary Heart" in Children with Bronchopulmonary Dysplasia: Incidence, Risk Factors, Therapy]. *Tezisy VII Vserossiiskogo kongressa «Detskaya kardiologiya-2012»* (Abstracts of VII Russian National Congress "Pediatric Cardiology 2012"). Moscow, 2012. pp. 230–1.
3. Northway W. H., Rosan R. C., Porter D. Y. Pulmonary disease following respiratory therapy of hyaline membrane disease. *N Engl J Med*. 1967; 276: 357–368.
4. Khemani E., McElhinney D. B., Rhein L., Andrade O., Lacro R. V., Thomas K. C., Mullen M. P. Pulmonary artery hypertension in formerly premature infants with bronchopulmonary dysplasia: Clinical features and outcomes in the surfactant era. *Pediatrics*. 2007; 120: 1260–9.
5. Galie N., Manes A., Negro L., Palazzini M., Bacchi Reggiani M. L., Branzi A. A meta-analysis of randomized controlled trials in pulmonary arterial hypertension. *Eur Heart J*. 2009; 30: 394–403.
6. Eulmesekian P., Cutz E., Parvez B., Bohn D., Adatia I. Alveolar capillary dysplasia: A six-year single center experience. *J Perinat Med*. 2005; 33: 347–52.
7. Abman S. H. Approach to the child with pulmonary hypertension and bronchopulmonary dysplasia. *Advances in pulmonary hypertension*. 2011; 10: 98–103.
8. Drossner D. M., Kim D. W., Maher K. O., Mahle W. T. Pulmonary vein stenosis: Prematurity and associated conditions. *Pediatrics*. 2008; 122: 656–61.
9. Seale A. N., Webber S. A., Uemura H., Partridge J., Roughton M., Ho S. Y. et al. Pulmonary vein stenosis: The UK, Ireland and Sweden collaborative study. *Heart*. 2009; 95: 1944–9.
10. *Klassifikatsiya klinicheskikh form bronkhologochnykh zabolovaniy u detei* [Classification of Clinical Forms of Bronchopulmonary Diseases in Children]. Moscow, Rossiiskoe respiratornoe obshchestvo, 2009. 18 p.
11. Davydova I.V., Kustova O.V. *Dinamika KT-priznakov bronkhologochnoi displazii v iskhode zabolovaniya* [Dynamics CT-signs of Bronchopulmonary Dysplasia in the Outcome of the Disease]. *Sbornik trudov KhIKh Natsional'nogo kongressa po boleznyam organov dykhaniya* (Proceedings of the XIX National Congress on Respiratory Diseases). Moscow, 2009. pp.140–141.
12. Yatsyk G.V., Davydova I.V., Kustova O.V. et al. *Patent na izobretenie № 2401066 ot 10.10.2010 «Sposob otsenki stepeni tyazhesti bronkhologochnoi displazii»* [Patent for the Invention № 2401066 "A method for Evaluating the Severity of Bronchopulmonary Dysplasia" dated 10.10.2010].
13. Davydova I.V. *Formirovanie, techenie i iskhody bronkhologochnoi displazii u detei. Avtoref. dis. ... dokt. med. nauk* [Formation, Course and Outcomes of Bronchopulmonary Dysplasia in Children. Author's abstract]. Moscow, 2010. 4 p.

Table 1. Pulmonary hypertension caused by pulmonary diseases and hypoxemia in the classification of hypertensive pulmonary vascular diseases in children (PVRI)

Category	Description	Examples
1	Prenatal or congenital hypertensive pulmonary vascular disease in children	1.2. Associated with fetal developmental disability of pulmonary vessels 1.2.1 Associated with fetal pulmonary hypoplasia 1.2.1 a. Idiopathic pulmonary hypoplasia 1.2.1 b. Familial pulmonary hypoplasia 1.2.1 c. Congenital diaphragmatic hernia 1.2.1 d. Hepatopulmonary fusion 1.2.1 e. “Scimitar” syndrome 1.2.1 f. Associated with fetal pulmonary compression: Oligohydramnios Omphalocele/gastroschisis Cystic adenomatosis Fetal tumors and tumor-like lumps 1.2.1 g. Associated with fetal skeletogeny maldevelopment 1.2.2. Associated with fetal pulmonary growth inhibition/maldevelopment 1.2.2 a. Acinous dysplasia 1.2.2 b. Congenital alveolar dysplasia 1.2.2 c. Dysplasia of alveolar capillaries with or without compromised location of pulmonary veins 1.2.2 d. Lymphangiectasia
4	Bronchopulmonary dysplasia	4.1. With hypoplasia of pulmonary vessels 4.2. With stenosis of pulmonary veins 4.3. With left ventricle’s diastolic dysfunction 4.4. With pulmonary-to-systemic shunts: Aortopulmonary collaterals Atrial septal defect Patent ductus arteriosus Ventricular septal defect 4.5. With significant hypercapnia and/or hypoxia
7	Pulmonary diseases in	7.1. Mucoviscidosis

	children	7.2. Interstitial pulmonary affections: surfactant protein deficiency etc. 7.3. Sleep-disordered breathing 7.4. Deformities of chest wall and spine 7.5. Restrictive pulmonary disease 7.6. Chronic obstructive pulmonary diseases
9	Hypobaric anoxia	9.1. High altitude pulmonary edema (HAPE) 9.2. Pediatric subacute mountain sickness 9.3. Monge disease 9.4. PPHN-associated hypobaric anoxia 9.5. Congenital cardiac diseases 9.6. Isolated PPHVD or PAH

Table 2. Radiographic scale for rating bronchopulmonary dysplasia (BPD) severity according to the multispiral computed tomography

Signs	Points		
	0-1	2	3
Pulmonary tissue pneumatization grade	Moderate increase	Increase, irregularity	Sharp increase, irregularity, bullae
Architectonics of lung pattern by lung lobes	Depleted, not deformed	Depleted, moderately deformed, expressed interstitial tissue	Acutely depleted on the periphery, deformed
Peribronchial alterations of pulmonary tissue	Insignificant	Moderate, narrowed bronchial lumina	Expressed, deformed lumina, bronchiectases
Pulmonary fibrosis spread	None	Unexpressed, singular commisures	Coarse fibrosis with signs of volume downsizing of segments, multiple transpulmonary bands
Cardiovascular alterations: pulmonary hypertension, megalocardiae	None	Moderate pulmonary hypertension, possible cardiomegaly	Expressed cardiomegaly or hypertrophy of the right ventricle, pulmonary hypertension
BPD severity assessment result	Mild 1-5 points	Moderate 6-10 points	Severe 11-15 points