

G.V. Revunenko, V.Yu. Yaltikov

Scientific Center of Children's Health, Moscow, Russian Federation

Clinical case of an isolated corrected transposition of the great arteries

Author affiliation:

Revunenko Grigori Valer'evich, MD, doctor at the department of ultrasonic diagnostics of the Consultative-Diagnostic Center of the Scientific Center of Children's Health

Address: 2/2 Lomonosovskiy Ave., Moscow, 119991; **tel.:** +7 (495) 967-14-20;
e-mail: rg07@mail.ru

Article received: 12.03.2014. **Accepted for publication:** 14.05.2014.

Corrected transposition of the great arteries (CTGA) is pathology of cardiovascular development rarely observed in therapeutic practice. This condition is difficult to diagnose due to the absence of both hemodynamic disorders and clinical manifestations in patients for a long time. Echocardiography is a method applied to perform timely diagnosis of this condition and develop an algorithm of dynamic observation and treatment.

Keywords: *corrected transposition of the great arteries, hemodynamic disorders, clinical manifestations, diagnosis, echocardiography, children.*

Corrected transposition of the great arteries (CTGA) is a rare congenital heart disorder, the rate whereof is 0.4-1.2% of all the congenital heart disorders [1, 2]. Anatomic essence of the disorder is as follows: bulboventricular inversion (at cardiac normotopia) results in left location of the morphologically right ventricle with branching aorta (also in left-hand-side location), whereas the morphologically left ventricle is observed on the right; the pulmonary artery branching therefrom is located to the right of the aorta. Development of the corrected transposition of the great arteries is considered to result from the disturbed primary ventricular loop torsion mechanism [2].

Schematic representation of the anatomical structures at this anomaly is given in pic. 1. The disorder is corrected, as the morphologically left ventricle communicates with the right atrium with the bicuspid valve and admits venous blood, whereas the morphologically right ventricle communicates with the left atrium with the tricuspid valve and admits arterial blood. That is why hemodynamic disorders are not observed at isolated CTGA (without associated disorders). This disorder is also characterized by various types of atrioventricular blockades (in ca. 70% of the patients) and resultant disorders of normal topography of the interventricular septum and the conduction system [3]. The blockade may be congenital or develop through life; initially it is intermittent, but becomes continuous with time. Left deviation of the cardiac electrical axis is usually observed in electrocardiograms at that point. Atrioventricular conduction disorder may be accompanied by dysfunction of the tricuspid valve and the morphologically right (arterial) ventricle in such patients, as they are not accustomed to the load upon arterial compartments of the heart.

CTGA may be accompanied by the following congenital heart disorders: interventricular septal defect (sometimes – multiple defects), pulmonary artery stenosis (usually – infundibular or membranous), patent ductus arteriosus and pulmonary artery hypoplasia [4]. In the event of the isolated rotational anomaly, corrected transposition of the great arteries and extracardiac pathology are not observed [5].

Prognosis for life in these patients is favorable. Implantation of an artificial pacemaker is indicated in the event of complete atrioventricular blockade. The disorder is surgically corrected in the event of complications with double-switch, which consists in the complete recovery of anatomical links.

CLINICAL CASE

Parents of child K., 3 months of age, applied to the consultative-diagnostic center of the Scientific Center of Children's Health for examination by the assignment of the local polyclinic due to complicated heart anatomy interpretation at the US. Anamnesis indicated that the doctors considered the probability of transposition of the great arteries in the neonatality, although this diagnosis was ruled out due to distinct nonconformity to the postnatal child's clinical pattern.

Objective examination data: regular physique, adequate nutrition. Smooth, regularly colored skin. Non-palpable peripheral lymph nodes. Vesicular respiration in lungs, no rales. Muffled heart tones, slight apical systolic murmur. Normal heart rate, 135 bpm. Arterial pressure – 85/40 mm Hg. Abdomen – soft on palpation, painless. Non-palpable liver and spleen. Unremarkable stool and diuresis. No deviations observed in clinical blood and urine analyses and biochemical blood analysis. Echocardiographic image (four-chamber view) raised suspicion of atrioventricular discordance (pic. 2). We identified the morphologically right ventricle with the moderator fassicle, pronounced trabeculation of the apex thereof and the corresponding tricuspid valve, which was larger than the mitral valve, by means of deductive echocardiography [6-8]. The morphologically left ventricle was identified with characteristic flatness of walls and presence of two groups of papillary muscles corresponding to the mitral valve. Pulmonary veins ran into the left atrium communicating with the anatomically right ventricle with the tricuspid valve. The right atrium communicated with the anatomically left ventricle with the mitral valve. The great arteries located almost parallel to each other were visualized along the long axis in the high parasternal position (pic. 3): the first is the aorta branching from the arterial ventricle, the second (found more deeply) is the pulmonary artery branching from the venous ventricle. Location of the great arteries is typical of the transposition.

Prognosis for life in these patients is favorable; follow-up observation consists in ECG and EchoCG with evaluation of disturbances of heart rate, intracardiac conduction, hemodynamics, dynamics of heart cavities and heart pump function.

Implantation of an artificial pacemaker is indicated in the event of complete atrioventricular blockade. The disorder is surgically corrected in the event of complications with double-switch, which consists in the complete recovery of anatomical links.

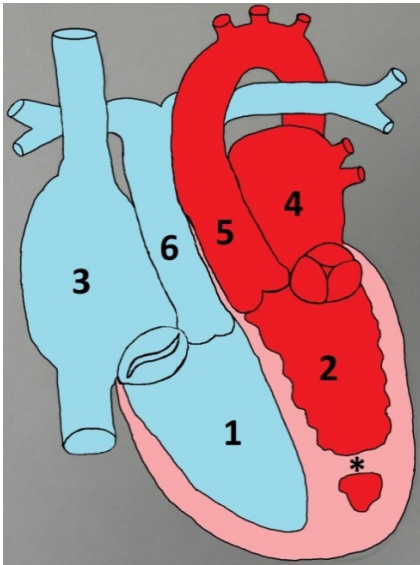
CONCLUSION

Thus, echocardiographic examination is one of the expert types of examinations; it helps to assess complex heart disorders, timely establish diagnosis and select treatment tactics.

REFERENCES

1. Mitina I. N., Bondarev Yu. I. *Neinvazivnaya ul'trazvukovaya diagnostika vrozhdennykh porokov serdtsa* [Noninvasive Ultrasound Diagnosis of Congenital Heart Disorders]. 2004.
2. Chazov E. A. *Rukovodstvo po kardiologii* [Guidance on Cardiology]. Moscow, Meditsina, 1982. 624 p.
3. Shiller N., Osipov M. A. *Klinicheskaya ekhokardiografiya* [Clinical Echocardiography]. Moscow, 1993. 344 p.
4. Feigenbaum H. *Ekhokardiografiya. Per. s angl. pod red. V.V. Mit'kova* [Echocardiography. Translated from English. Edited by V.V. Mit'kov]. Moscow, Vidar, 1999. 512 p.
5. Braunwald E. Heart disease. A Textbook of Cardiovascular Medicine. Philadelphia, 1988.
6. de la Cruz M.V., Arteaga M., Espino-Vela J., Quero-Jimenez M., Anderson R.H., Diaz G.F. Am Heart J. Complete transposition of the great arteries: types and morphogenesis of ventriculoarterial discordance. 1981 Aug; 102 (2): 271–81.

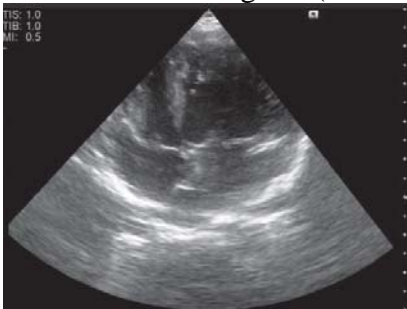7. Harold D. Rosenbaum, Edmund D. Pellgrino, Leo J. Treciokas. Acyanotic Levocardia. *Circulation*. 1962; 26: 60–72. Online ISSN: 1524–4539.
8. Feigenbaum H. Cardiac ultrasound. London, 1993.



Pic. 1. Schematic anatomical representation of the compensated transposition of the great arteries

Note. 1 – morphologically left (venous) ventricle, 2 – morphologically right (arterial) ventricle, 3 – right atrium, 4 – left atrium, 5 – aorta, 6 – pulmonary trunk, * - moderator fassicle.

Pic. 2. Echocardiogram (four-chamber view). Atrioventricular discordance



Pic. 3. Echocardiogram (along the long axis in the high parasternal position). Transposition of the great arteries

